

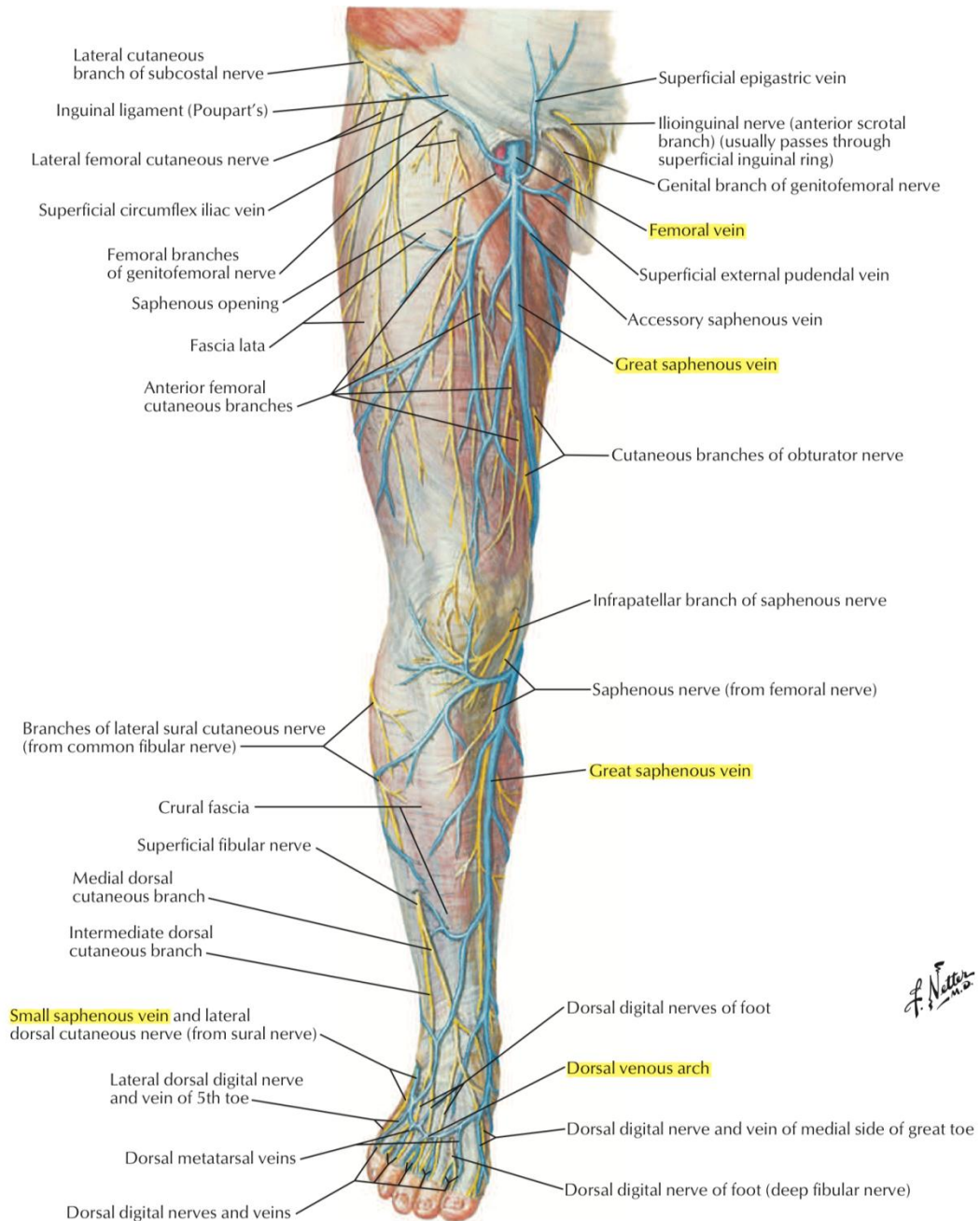
# BLOOD SUPPLY OF THE LOWER LIMBS

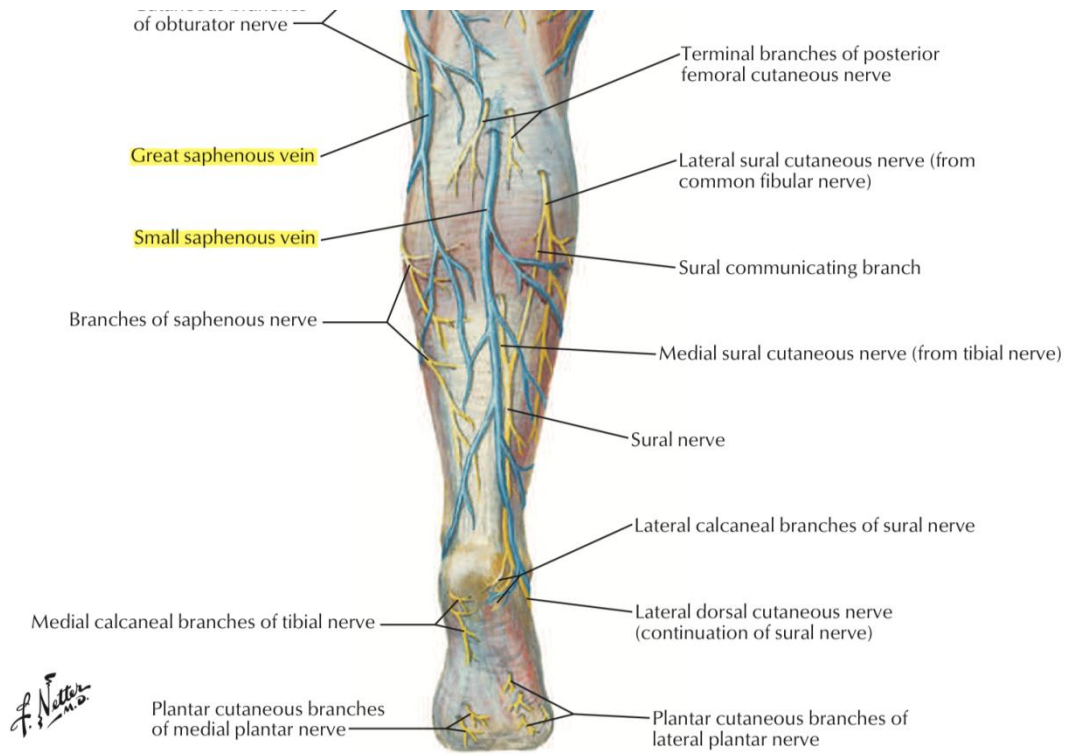
## Arterial:

1. Femoral artery.
2. Popliteal artery.
3. Tibial artery (Anterior & posterior).
4. Fibular artery.
5. Dorsalis pedis artery.
6. Medial and lateral plantar arteries.

## Venous:

1. Femoral vein.
2. Great saphenous vein.
3. Small saphenous vein.
4. Dorsal venous arch.





**Second layer tendons and muscles in bold**

