ANATOMY……___ L. Zahra Mousa Hamza/nursing 1st class

Anatomy – the study of the structure of body parts and their relationships to one another.

Physiology : the study of the function of the body's structural machinery.

Clinical anatomy: It's the study of the macroscopic structure and function of the body and its related to the practice of the medicine and other healthy science .

***Gross or macroscopic**

Regional – all structures in one part of the body (such as the abdomen or leg)

Systemic – gross anatomy of the body studied by system **.**

Surface – study of internal structures as they relate to the overlying skin.

***Microscopic**

Cytology – study of the cell.

Histology – study of tissues.

Developmental anatomy: structural changes over time

Embryology – study of developmental changes of the body before birth

Specialized Branches of Anatomy:

-**Pathological anatomy** – study of structural changes caused by disease.

-**Radiographic anatomy** – study of internal structures visualized by X- ray.

-**Molecular biology** – study of anatomical structures at a sub-cellular level.

Anatomical position:

1.Body erect. 2.Feet slightly apart. 3.Palms facing forward. 4.Thumbs point away from body

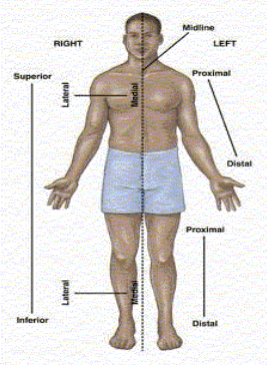

Directional terms and relations:

Anterior	In front of or front
Posterior	In behind of or behind
Ventral	Towards the front of the body
Dorsal	Towards the back of the body
Distal	Away or farthest away from the trunk or the point of origin of the body part
Proximal	Closer or towards the trunk or the point of origin of the body part
Median	Midline of the body
Medial	Towards the median
Lateral	Away from median
Superior	Towards the top of the head
Inferior	Towards the feet
Cranial	Towards the head
Caudal	Towards the tail
External	Towards the surface, superficial

Internal	Away from the surface, deep
Superficial	Nearer to the surface
Deep	Farther from the surface
Palmar	Anterior hand or palm of hand (palmar)
Dorsal (of hand)	Posterior surface of hand (dorsum)
Plantar	Inferior surface of foot (sole)
Dorsal (of foot)	Superior surface of foot (dorsum)

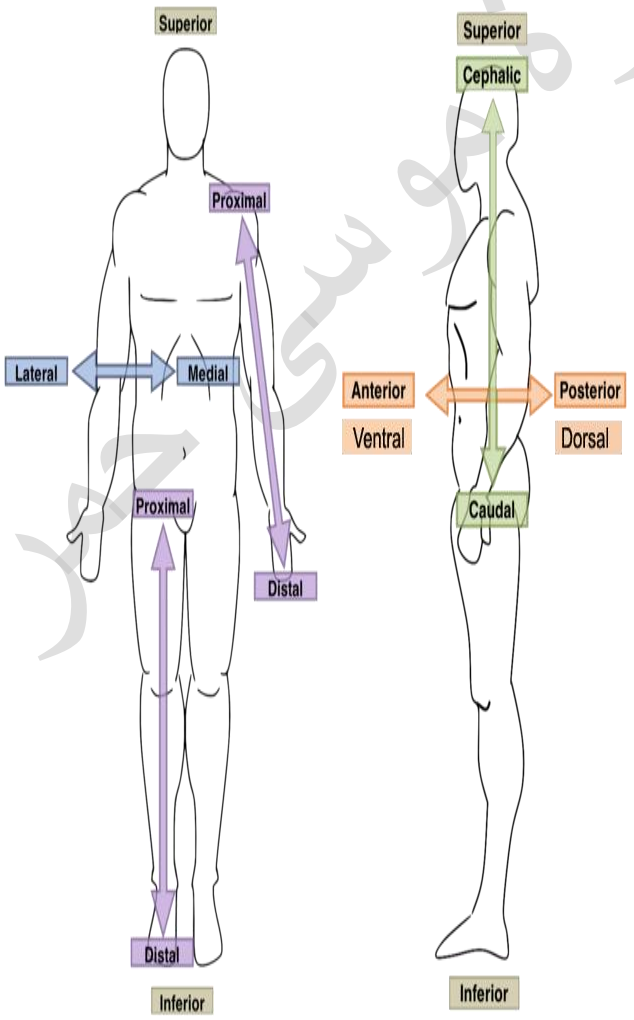

names of some sites of the body:

Brachial = arm Buccal = cheek Carpal = wrist

Celiac = abdomen Cephalic = head Cervical = neck

Costal = ribs Digital = finger Dorsal = back

Femoral = thigh Frontal = forehead Genital = reproductive

Gluteal = buttocks Lumber = region of the lower back between the ribs and pelvis lion

Mammary = breast Nasal = nose Orbital = eye cavity

Otis = ear Palmer = palm of the hand Pedal = foot

- Sternal = middle of thorax (sternum)

Body Planes:

***Sagittal** – divides the body into right and left parts.

Midsagittal or medial – sagittal plane that lies on the midline.

* **Frontal or coronal** – divides the body into anterior and posterior parts.

* **Transverse or horizontal** (cross section) – divides the body into superior and inferior parts.

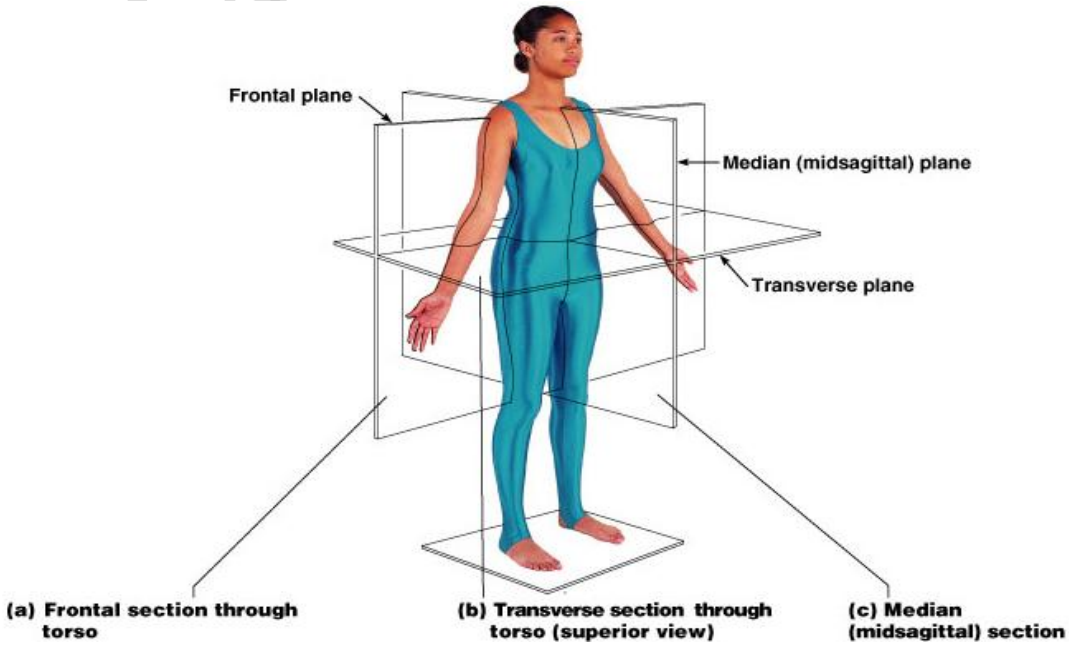

Body Cavities:

*__Dorsal cavity:__ protects the nervous system , and is divided into two subdivisions

-- **Cranial cavity** : is within the skull and encases the brain

--**Vertebral cavity** : runs within the vertebral column and encases the spinal cord.

***Ventral cavity:** houses the internal organs (viscera), and is divided into two subdivisions:

-- Thoracic cavity.

-- Abdominopelvic cavity.

***Thoracic cavity** is subdivided into

--**Pleural cavities** – each houses a lung

--**Mediastinum** - contains the pericardial cavity, and surrounds the remaining thoracic organs

-**Pericardial cavity** – encloses the heart.

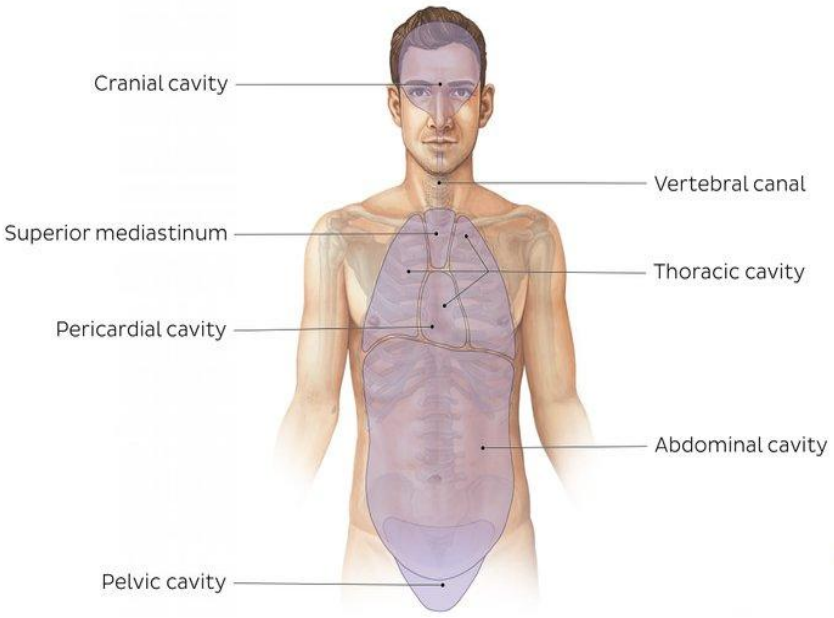

The abdominopelvic - cavity is separated from the superior thoracic cavity by The dome-shaped called diaphragm

It is composed of two subdivisions:

-**Abdominal cavity** – contains the stomach, intestines, spleen, liver, and other organs.

-**Pelvic cavity** – lies within the pelvis and contains the bladder, reproductive organs, and rectum

*__Oral cavity__ – mouth cavity.

*__Nasal__ cavity –located within and posterior to the nose.

*__Orbital__ cavity – house the eyes.

*__Middle ear__ cavity – contain bones that transmit sound vibrations.

*__Synovial__ cavity – joint cavities

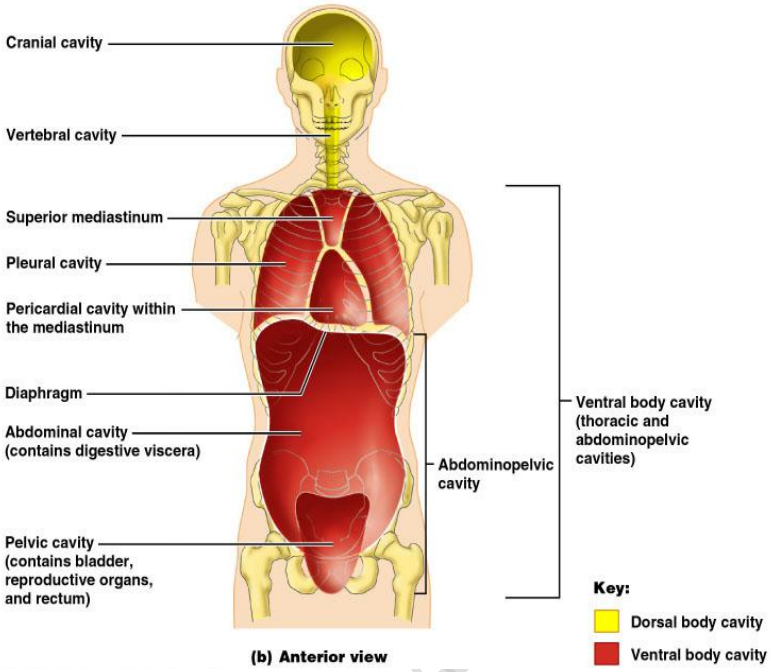

(b) Anterior view

***Abdominopelvic Regions**

1.Umblical

2.Epigastric

3.Hypogastric

4.Right and left iliac or inguinal

5.Right and left lumbar

6.Right and left hypochondriac

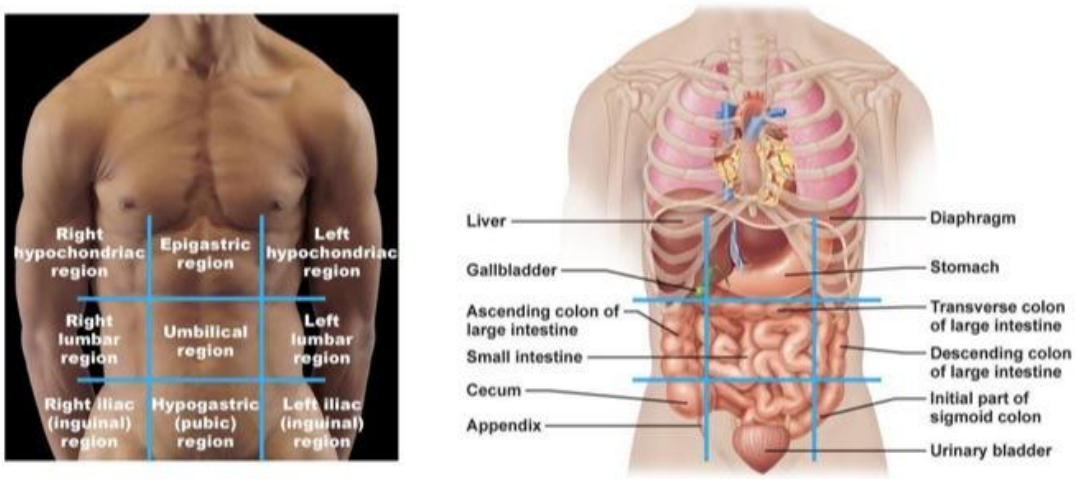

(a) Nine regions delineated by four planes (b) Anterior view of the nine regions showing the superficial organs

Cells

THE CELL: All living matter is composed of functional units called cells

Parts of the Human Cell

The various parts of the human cell and their functions are:

1.Cell Membrane:

This is the outer layer of the cell. It gives the cell its shape and holds the liquid inside the cell. This membrane is a semi-permeable membrane which means it allows certain things to pass in and out of the cell.

2. Nucleus:

The nucleus contains the nucleolus; this is the part of the cell which holds the genetic material, the chromosomes and chromatin which are concerned with reproduction of the cell.

3.Nucleolus:

A spherical body inside a nucleus made of protein, RNA and DNA. The nucleolus is involved in the synthesis and storage of ribosomal RNA.

4.Cytoplasm: This is the fluid inside the cell which contains salts and sugars in solution..

5.Golgi Apparatus:

This stores food inside the cell. Also note the fat droplets which float about in the cytoplasm and are also a means of storing food in the form of fats. Also called Golgi complex.

6.Lysosomes: These are digestive centers in the cell and help to digest and break down food material.

7.Centriole:

This is concerned with cell division, the reproduction of the cell and the movement of cell chromosomes.

8.Mitochondrion:

This is concerned with the respiration of the cell. As the end product of all respiration is energy, it is also a source of energy.

9.Endoplasmic Reticulum: This is the part where protein is manufactured or built up from nitrogen.

10.Fibrils: These are concerned with nervous responses.

11.Microtubule: These are tiny tubes inside the cells.

12.Microvilli: Tiny finger like bumps in the surface of the cell (ie. bumps in the cell wall) These serve to increase the surface area of the cell, hence improving the ability to absorb particles into the cell.

13.Cilia: Long hair or tail like structure projecting from a single cell, used to propel the cell (enables it to move or swim).

14.Chromatin: A mass of thread like genetic material, mainly DNA, present inside the nucleus when the cell is not dividing/reproducing.

15.Nuclear Envelope: Wall of material surrounding/containing the nucleus.

16.Glycogen: Complex polymer (compound) of glucose. This acts as a storage/supply of glucose on liver and muscle cells.

17. Peroxisome: Similar to lysosomes; an organelle containing enzymes that use oxygen to oxidize different organic compounds. These are common in liver cells.

18.Microfilament: A filament of protein. They are contractile units in muscle cells. They provide support, shape and movement in non-muscle cells.

19.Free Ribosomes: An organelle suspended in cytoplasm that synthesises proteins.

Contains ribosomal RNA and ribosomal proteins.

20.Secretory Vesicle: Tiny bladder or sac in the cell that secretes or expels unwanted material.

Although the cell is very, very small, you can see that it contains many different parts It

also carries out many different functions.

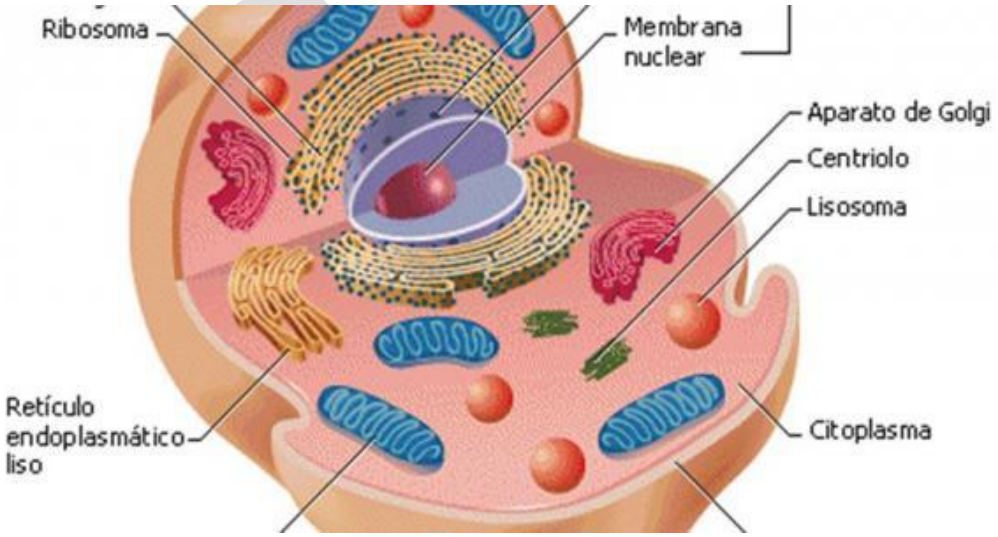

Tissues

Its formed of collection of similar cells :

There are five basic types of tissue found in humans:

§ Epithelial tissues § Connective tissues

§ Muscle tissues § Nervous tissues

1.Epithelial tissues:

A-Simple : consist of a simple layer of flattened or cubical or columnar (G.I.T)

B-Compound : which is composed of several layers (Endocardium ,Pleura, peritoneum)

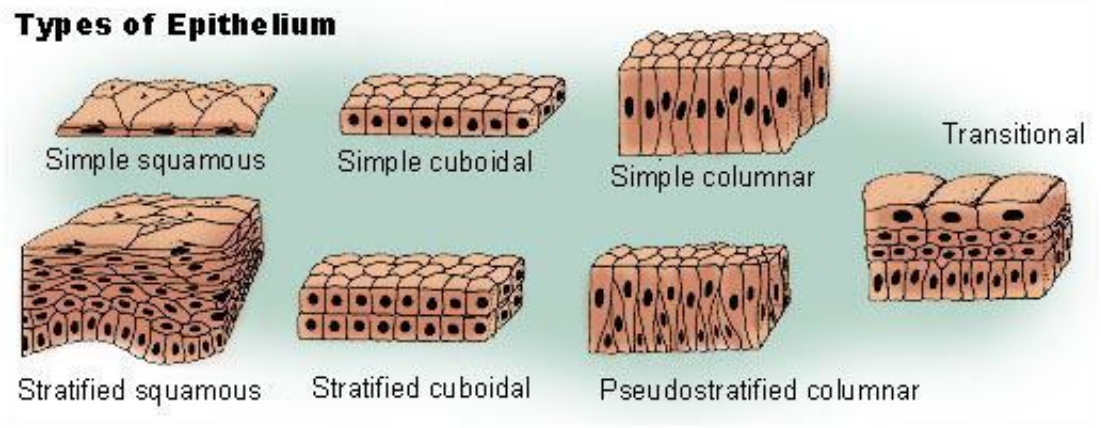

2.Connective tissues:

This is the tissue which joins other tissues together. Connective tissues give form and strength to many organs, and often serve for protection and leverage. Examples of connective tissue are: bones; tendons; ligaments; cartilage blood and fat.

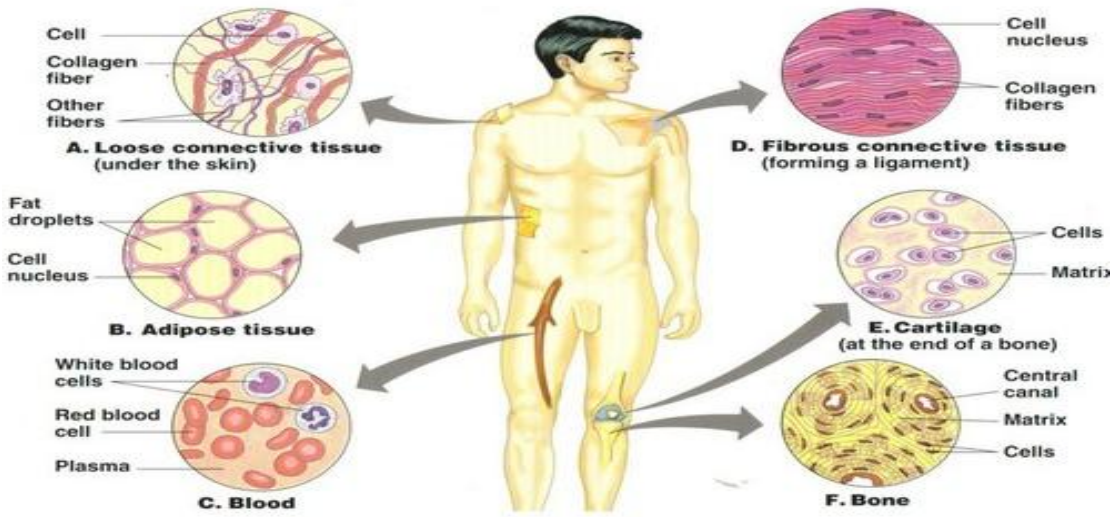

3.Muscle tissues: There are three types of muscle tissues:

* **Striated or voluntary muscle tissue** :which is the type found in the arms and legs. Skeletal muscle is made up of striated muscle fibers.

***Smooth or involuntary muscle tissue:** works automatically and cannot be controlled.

Involuntary muscle tissue would be found in the muscle in the intestine which moves food along though the gut.

***Cardiac muscle tissue** is also involuntary and cannot be controlled . This type of muscle tissue is found in the heart.

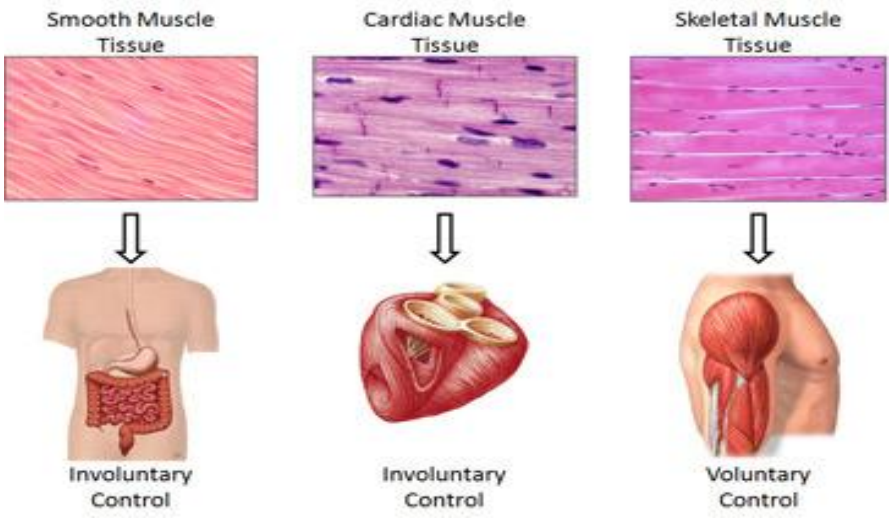

4. Nervous tissue:

The nerve cells which make up this tissue are sensitive to stimuli, such as heat and touch. They can link up charges and transmit impulses through the nervous system.

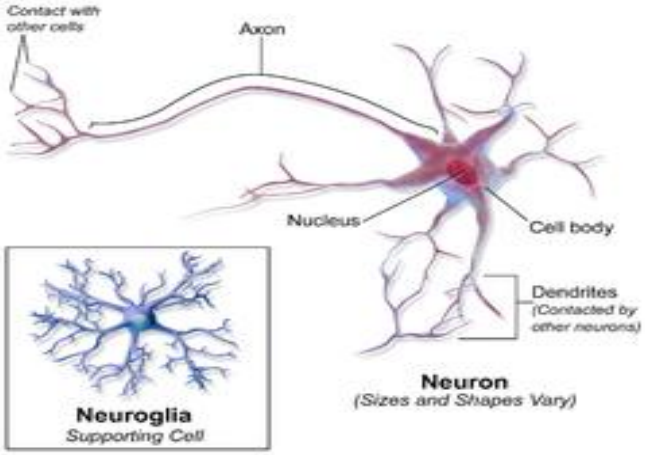

Neural Tissue

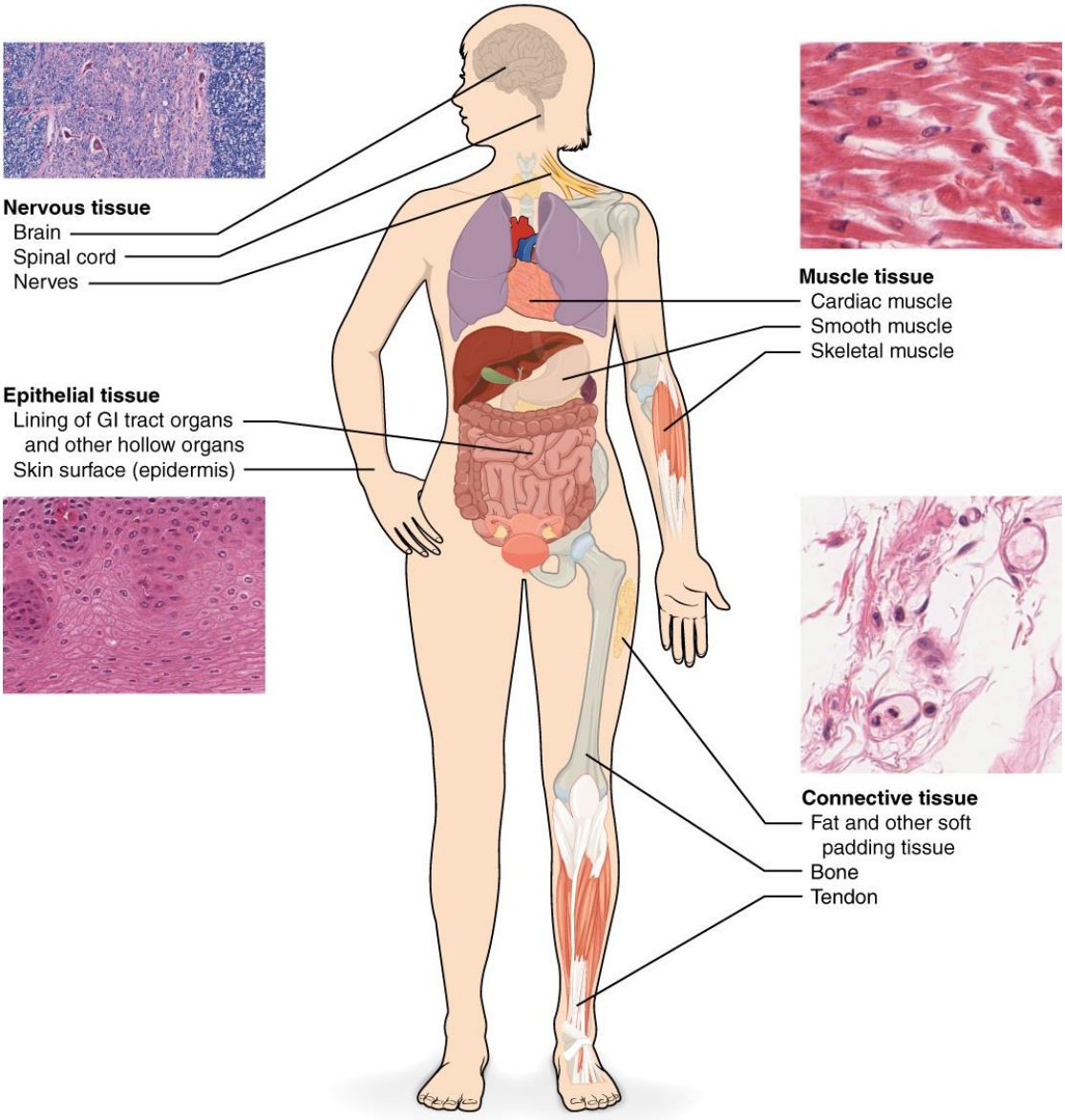
Nervous tissue
Brain
Spinal cord
Nerves
Muscle tissue
Cardiac muscle
Smooth muscle
Skeletal muscle
Epithelial tissue
Lining of GI tract organs
and other hollow organs
Skin surface (epidermis)
Connective tissue
Fat and other soft
padding tissue
Bone
Tendon

Anatomy of Skeleton System

Its multiple groups of skeletal parts that joints together by cartilage

*** Skeleton system divided into (2) main part:**

1-Central bones: Which consist from : 1- skull . 2- vertebral column .

2-Peripheral bones : Which consist from: 1- upper limb. 2-Lower limb.

functions:

1.Support

2.Protection (for internal organs)

3.Movement

4.Storage of blood cell-producing cells

5.Storage of minerals and fats

Types of Bones

1.Long bones (e.g. thighs, legs, toes, arms, forearms, and finger)

2.Short bone s (e.g. wrist, ankle bones)

3. Flat bones (e.g. cranial bones , sternum, ribs, scapulas)

4.Irregular- odd shapes (vertebrae, pelvis)

5. Sesamoid bones: All people have at least two sesamoid bones: the patella .

***The longest bone = femur. *The smallest bone is = stirrup [ears]**

***Bones make up 20% of the body's mass.**

Number of bone in human body are (206) bones

Skeleton of the Upper limb :

Its consist from :

1-Skeleton of the shoulder:

*** clavicle bone: The clavicle is along slender bone lies horizontal across the neck**

*** scapula :The scapula is a flat triangular bone that lies on the posterior .**

There are three angle to the scapula (superior ,inferior ,lateral angle).

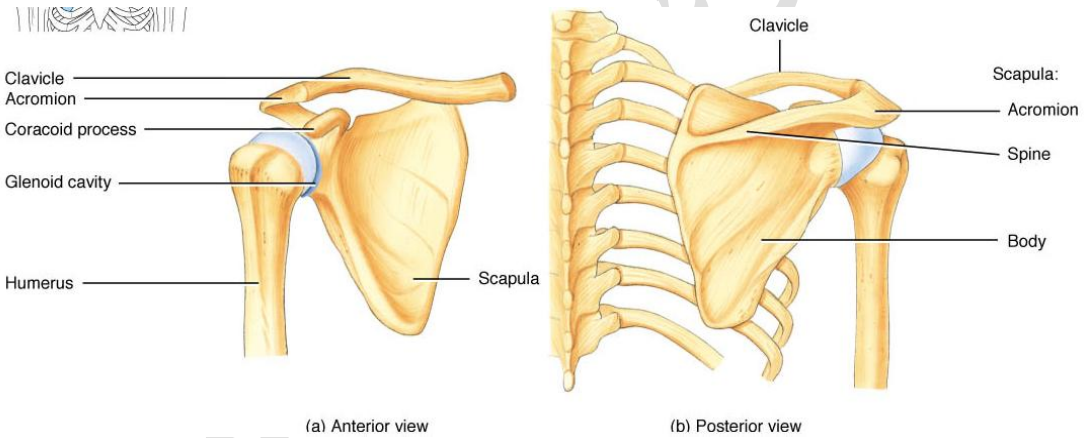

2-Skeleton of the upper arm (Hummers bone): Its long & strong bone in the upper arm which consist from (head, anatomical neck ,greater tuberosity +lesser tuberosity + inter-tubercular groove +shaft and lower end .

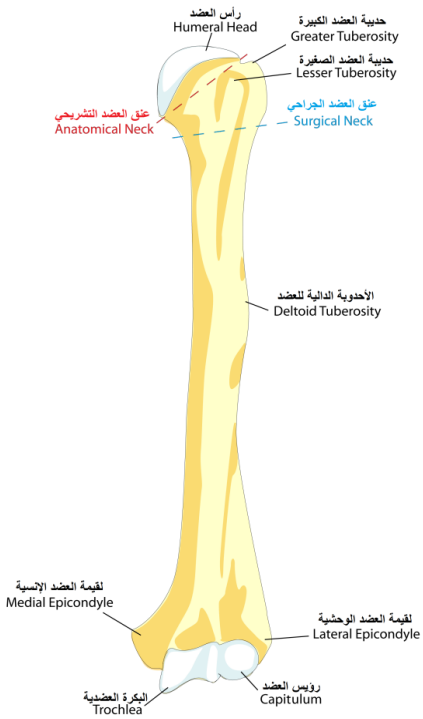

3- Skeleton of the forearm:

*Radius : Which is lateral bone consist of head , neck , radial tuberosity shaft and lower end called lateral styloid process that to the bone of the wrist by wrist joint .

***Ulna:** Its long bone consist of upper end (olecranon process trochlear notch coronoid process radial notch),

shaft and lower end. Called medial styloid process between the two bones there is inter-osseous space .

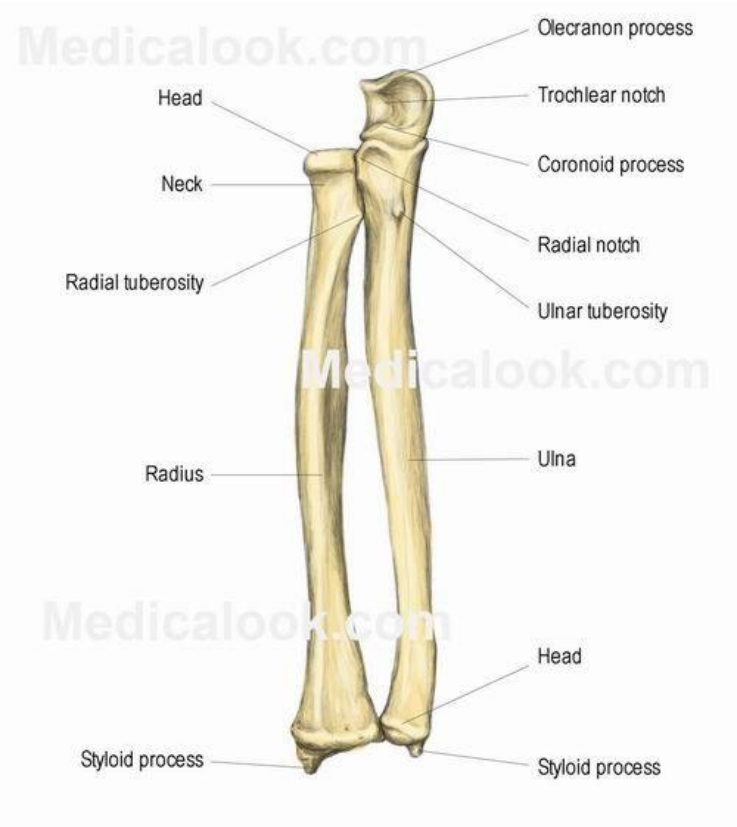

4- Skeleton of the hand :

skeleton of wrist which consist from 8 carpal bones). Bones made of two row of four bones in each raw .

*The proximal consist from (lateral to medial) scaphoid , lunate , triquetral , pisiform .

*The distal row consist from (trapezium , trapezoid , capitates and hamate

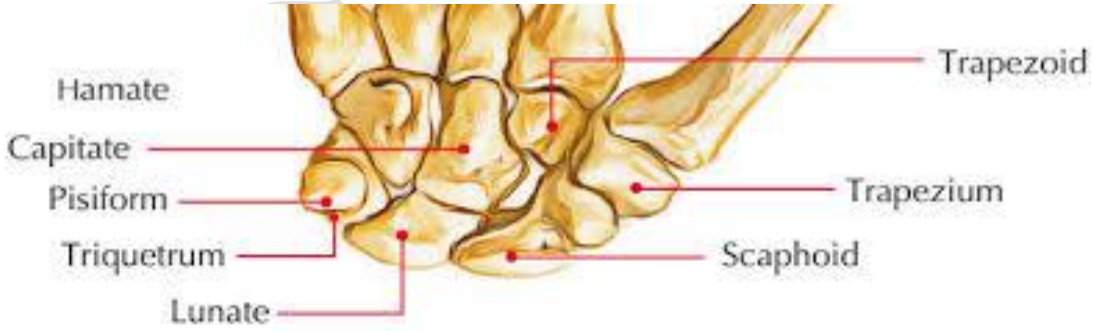

5-Skeleton of the palm (which consist from 5 metacarpal bones).

*1st metacarpal bone of the thumb is the shorter and mobile .

6-Skeleton of the fingers (which consist from phalanges).

There are three phalanges of the fingers but only two for the thumb.

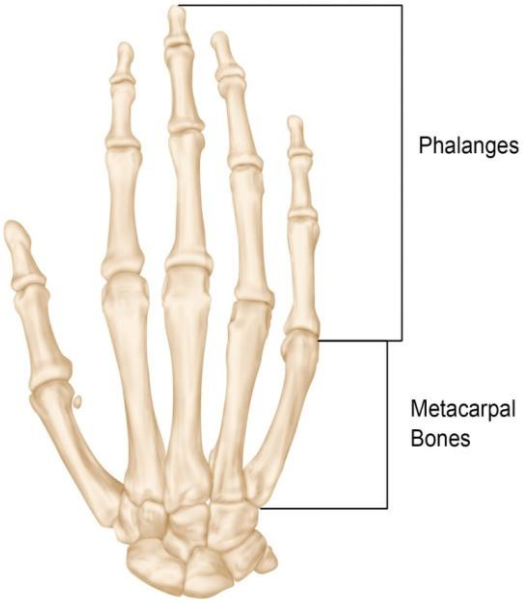
Phalanges
Metacarpal
Bones


DISTAL PHALANX
MIDDLE PHALANX
PROXIMAL PHALANX
DISTAL PHALANX
PROXIMAL PHALANX
METACARPAL
TRAPEZOID
TRAPZIUM
CAPITATE
SCAPHOID
LUNATE
RADIUS
PHALANXES
METACARPUS
HAMATE
TRIQUETRUL
CARPUS
PISIFORM
ULNA
PAUL JARRETT 2016

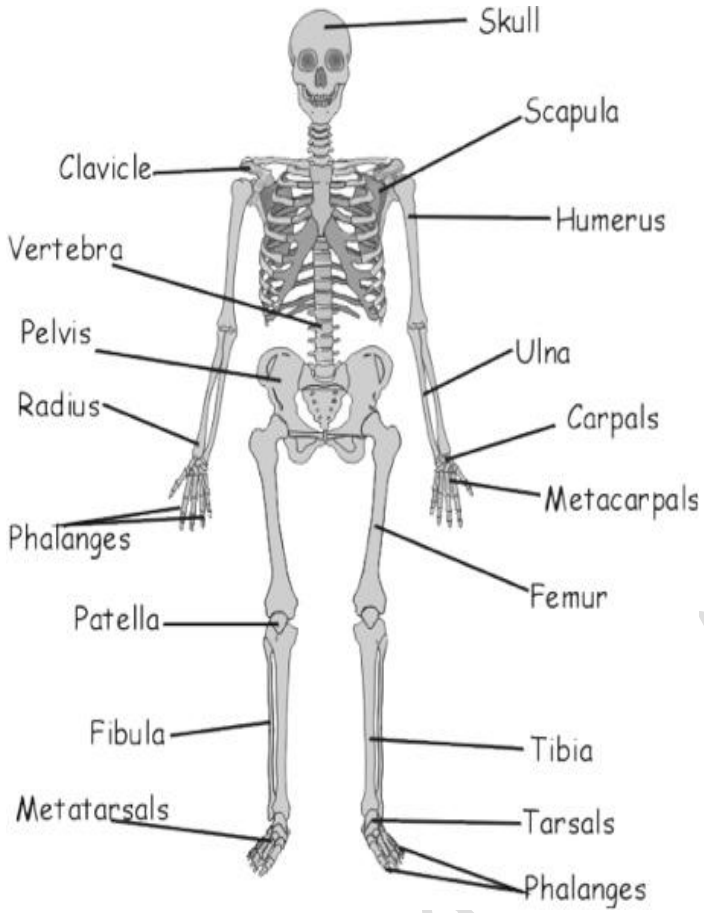

<u>Lower limb</u>

The primary function of the lower limb is

*to support the weight of the body

* to provide stable in standing , walking and running .etc .

The lower limbs are divided into many regions:

1-Gluteal region . 2-Thigh . 3-Knee. 4-Leg . 5-Ankle joint . 6-Foot.

Gluteal region : Which consist from:

***Hip bone :**

Its consist from two big bones which articulate anterior by symphysis pubis and posterior to the trunk by strong joint sacroiliac joint.

***They protect the structures which is part of abdomen,**

****it connected the trunk to the lower limb**

***** control the weight of the body on it.**

Its consist from three bone united together (Ileum ,pubis, ischium).The outer

surface of hip bone is deep depression called Acetabulum . That articulates to the femur bone .

Sacral bone :

Which consist from (5) big vertebra connect together which is triangular in shape, its base articulate with the 5th lumber vertebra, and the apex to the down articulate with coccyx .

Ilium bone : Its consist from :

1-Gluteal surface . 2-Iliac fosse . 3-Sacropelvic surface .

Pubis bone

Which consist from body , superior ramus, inferior

Obturator foramen :(which is passage of the obturator artery and nerve .

Ischium bone

Which is the lower part of the pelvic bone , its shape as (v) .

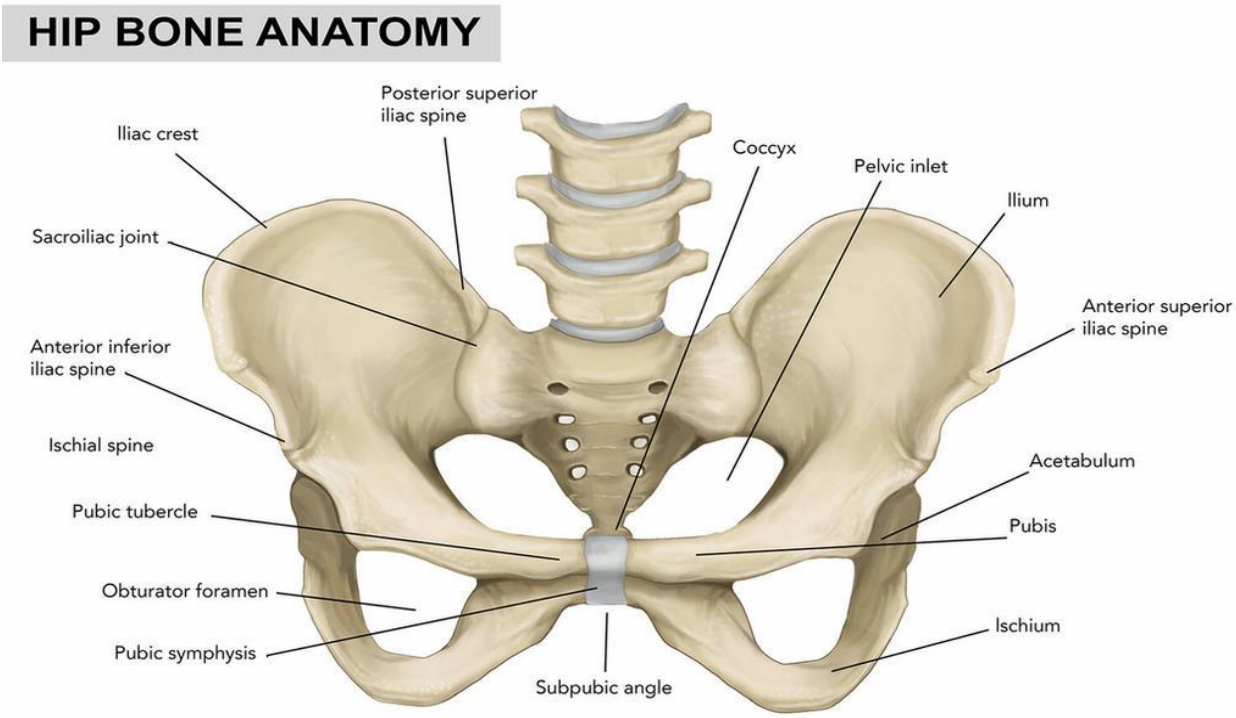

Thigh: Femur bone its strong and long bone . It has

(head ,neck ,greater and lesser trochanter , shaft(linea aspira posteriorly) ,

lower end (lateral and medial epicondoyle) (lateral and medial condoyle)

(intercondyle notch posteriorly patellar surface anteriorly)

The lower end articulated to knee joint to articulate to patella .

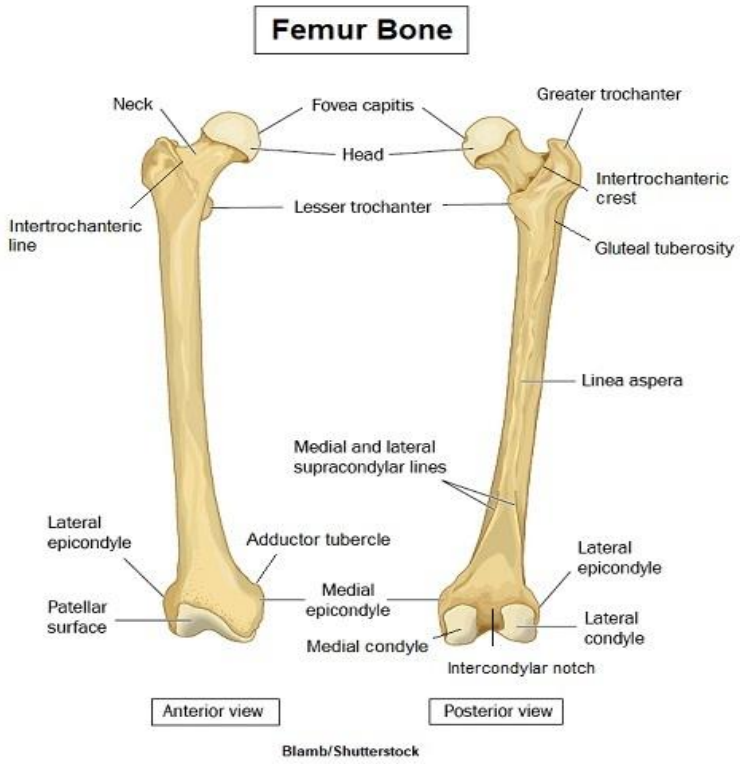

Leg:

1-Patella : It's the largest sesamoid bone triangle in shape , its attached to the tendon of the quadriceps femoris muscle .

2-Tibia : Its medial bone consist from upper end (head), shaft , lower end

(medial melleulue).

3-Fibula :Its lateral bone has head , shaft , lower end (lateral melleulue) .

Its function to Protect the tibia and in movement the foot outer and inner, **between the two bones has interosseous membrane.**

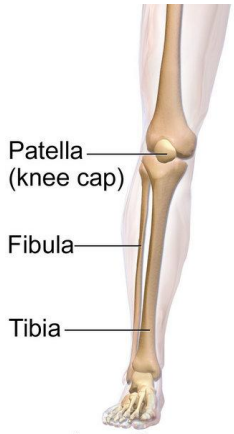

Leg Bones

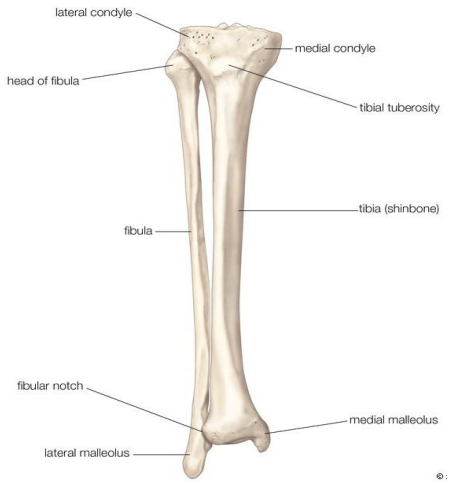

Skeleton of the ankle: Its consist from

*tarsal bones , its consist from 7th bones in two rows

the posterior row has two bones **(Talus and Calcareous)**

while the anterior row has 4 bones **(Cuneiform bone which is medial ,lateral ,intermediate)**

+Cuboids bone . The 7 bone is Navicular bone.

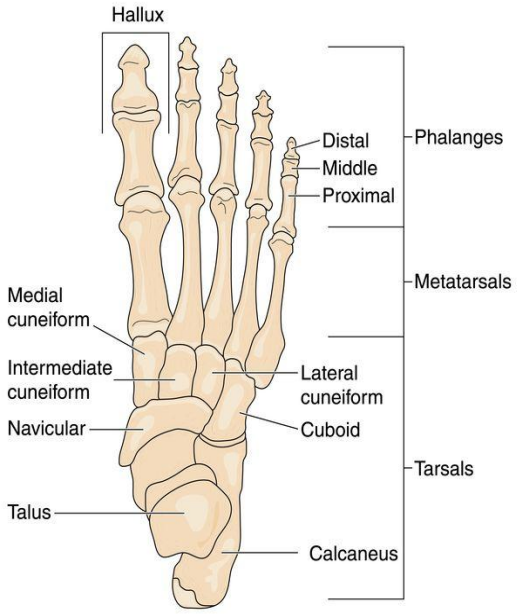

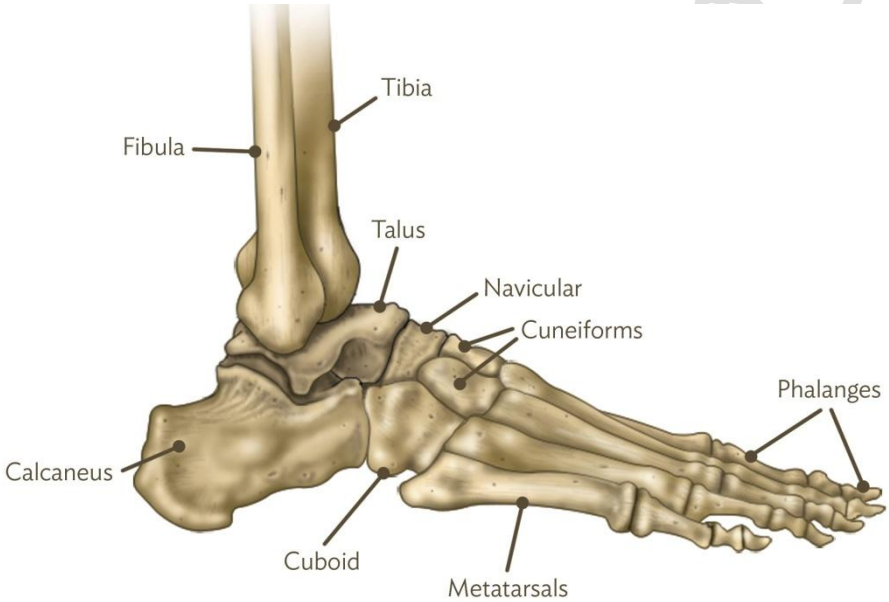

Skeleton of the sole:

They consist from 5 metatarsal bones , each has base articulated with the anterior row of the ankle . the 1st is (big toe) , the 5th (little toe) .

Skeleton of the Toes

They contains of phalanges ,its small bone each toe has 3 phalanges except the Big toe has two .

Transverse arch:

Its more in the metatarsal bone , it has important in walking depend on strong tendon that help by muscles for protect the arch .

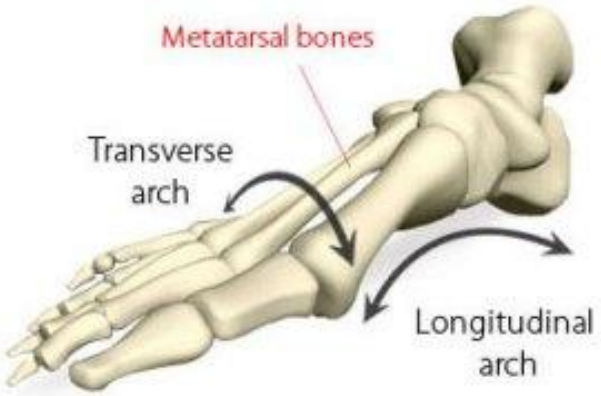
Metatarsal bones
Transverse arch
Longitudinal arch

Arches

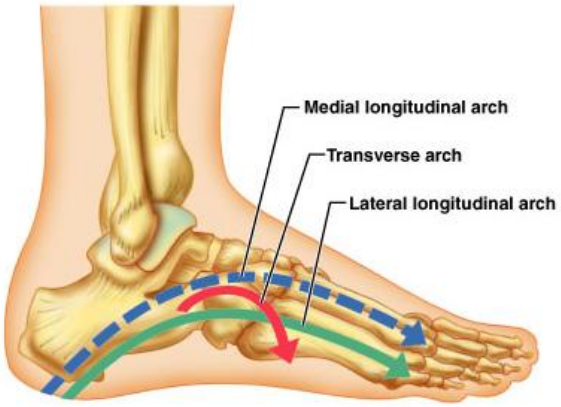
Medial longitudinal arch
Transverse arch
Lateral longitudinal arch

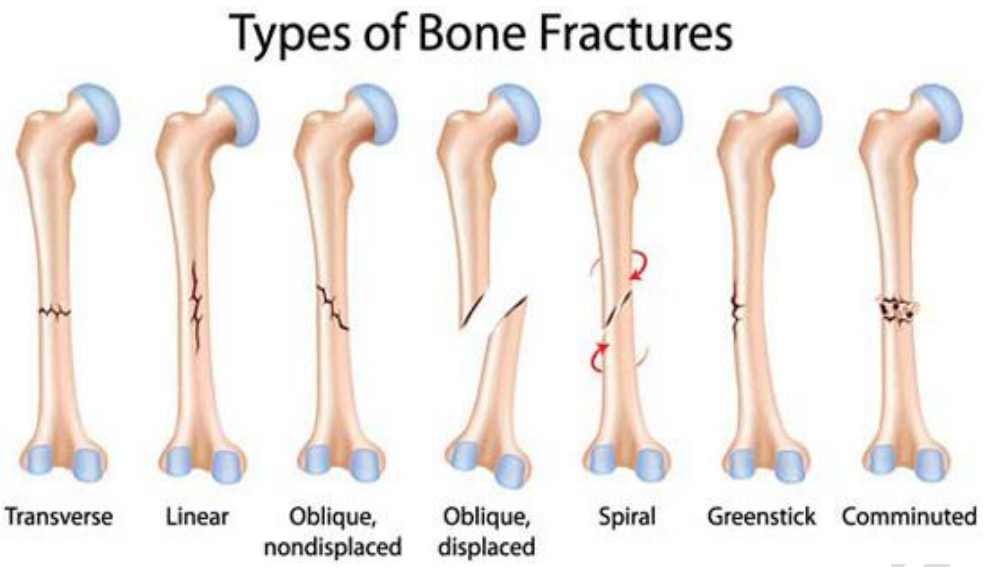

Central bones

Skeleton System

The skull

The skull has(22) bones and formed of 2 sets of bones (cranium) and (face).

All these bones are connected at immobile joints called sutures except

The mandible which is connected to the skull by freely movable joint.

Sutures are:

1.coronal suture. 2.sagittal suture. 3.lambdoid suture. 4.squamous suture

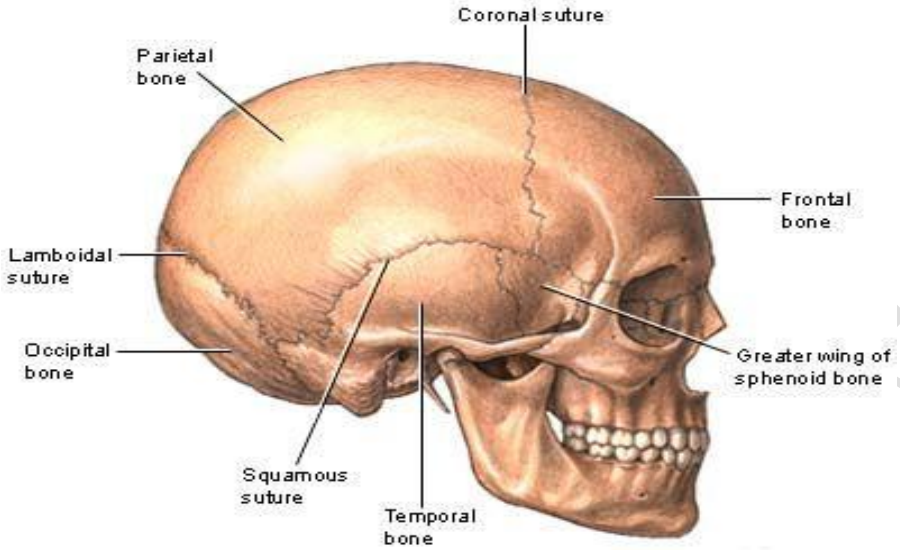

Bones of the cranium :-

Single bones :

1.Frontal bone ; In the front

2.Occipital bone ; in the back

3.Ethmoid bone ;in the base

4.Sphenoid bone ; in the base

Paired bones :- One on each side

1.parietal bones (2) bones above.

2.Temporal bones (2) bones below.

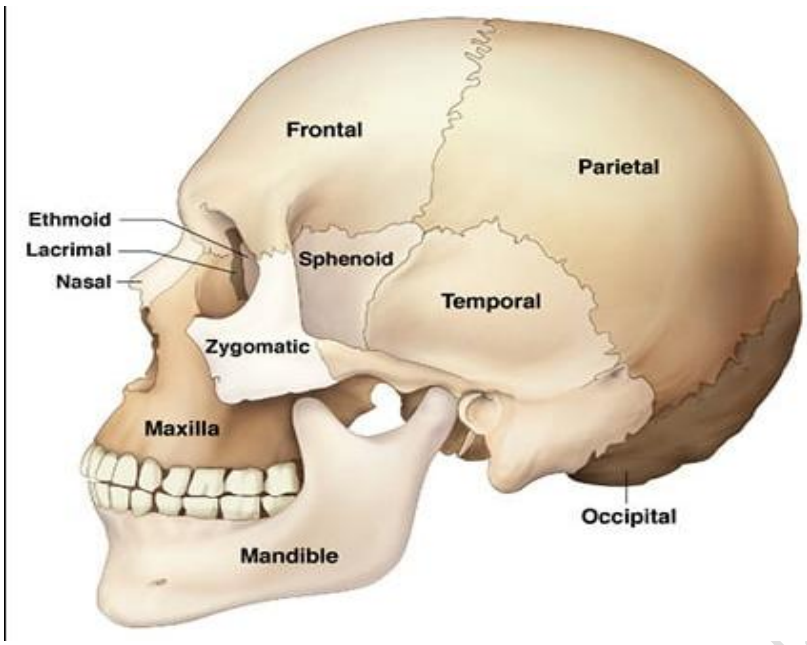

Bones of the face :-

They hold the eyes in the anterior position and allow the facial muscles to express our feelings . They consist of (14) bone (two single and (12) paired)

Single bones :- In the middle .

1.vomer :- forms most of the nasal septum

2.mandible:- forms the lower jaw

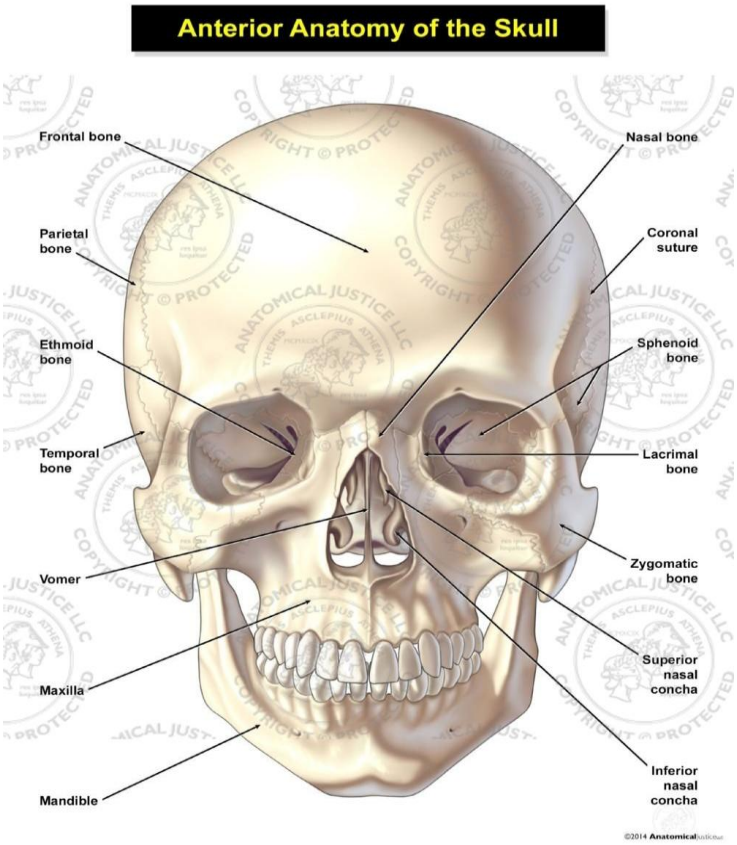

Paired bones :-

1.maxillae (2) :- They fuse together to form the upper jaw .

2.palatine bones (2) :- They are found behind the maxillary processes and form the posterior part of the hard palate

3.Zygomatic bones (2):-They form the bones of the cheek and also form a part of the lateral wall of the orbit (eye socket) .

4.Lacrimal bones (2)They form the bridge of the medial wall of the orbit each bone carries a groove for passage of tear(lacrima) These bones are small in size

5.Nasal bones (2):- They form the bridge of the nose.

6.Inferior conches (2):- They are thin curved bones. Each bone appear projecting from the lateral wall of the nose

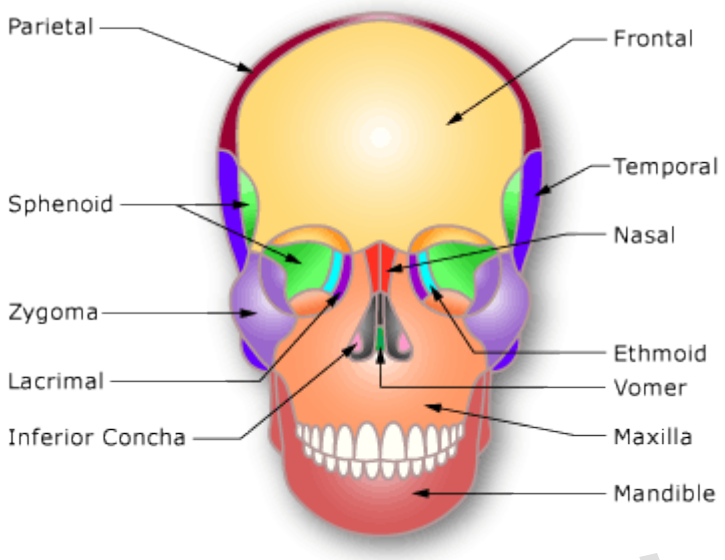

Thoracic cage:

Consist of the followings:

a. Ribs

b. thoracic Vertebrae

c. sternum :consist of : manubrium .. body.. xiphoid process.

d. costal cartilages

* True ribs are directly attached to the sternum (first seven pairs) by costal cartilages

* false ribs are joined to the 7th rib at 7th costal cartilage (Three pairs)

* floating ribs (Two pairs).

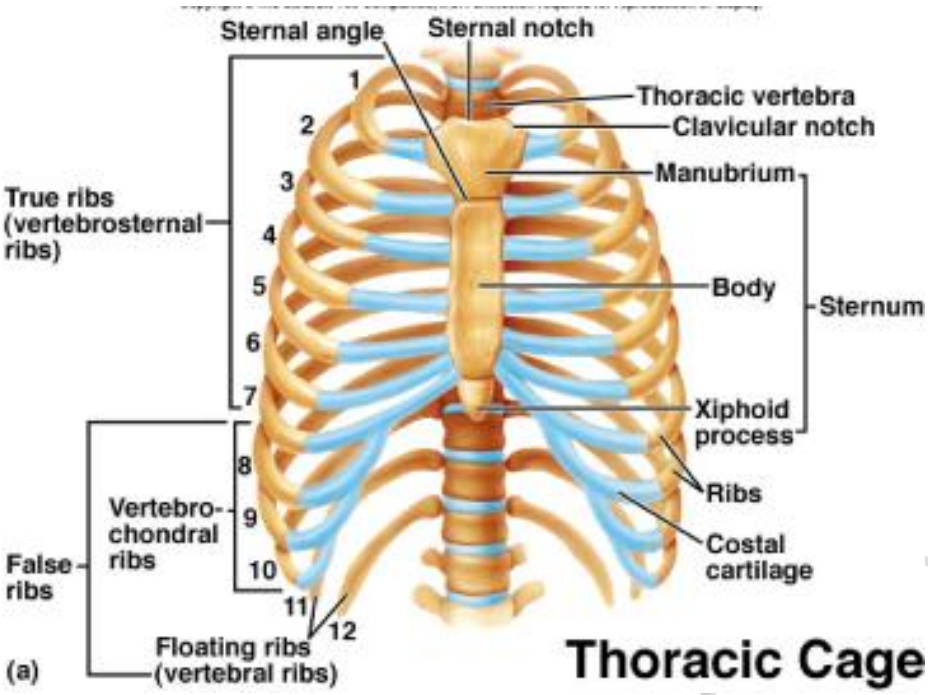

Vertebral column

It's the back which extent from the skull to the tip of coccyx , and can be define as the posterior surface of the trunk. It the central-bony pillar of the body , its support the skull , shoulder girdle , upper limbs , and thoracic cage , and by way of the pelvic girdle transmit

the body weight to the lower limb .

Within its cavity lie the spinal cord , roots of the spinal nerves and the covering meanings

to which the vertebral column gives great

The vertebral column composed from 33 vertebrae :

7 cervical ; 12 thoracic ; 5 lumber ; 5 sacral (fused to form the sacrum) and 4 coccygeal (the lower 3 are fused)

1-Cervical vertebrae

Its (7) vertebrae , the 1st one called Atlas which articulate with the occipital bone of the skull by Atlanto-occipital .

The 2nd vertebrae called Axis which support the movement of the atlas vertebrae and skull .

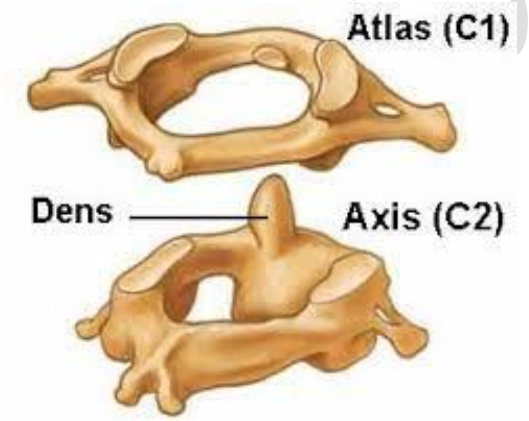

2-Thoracic vertebrae

Its (12) vertebrae each one has big body + long spine , its articulate with the ribs of the chest

3-Lumbar vertebrae

They are (5) in number , it's the biggest one in the vertebral column, it has restriction in movement, and has kidney shape , the vertebral canal is triangular in shape .

4-Sacral vertebrae

They are (5) vertebrae ,t hey are joint together to form sacrum bone , which is triangular in

shape ,the base is in the upper and the apex in the lower part , articulated with coccyx .

5- <u>Coccygeial vertebrae</u>

Its small bone triangular consist from (4) vertebrae .

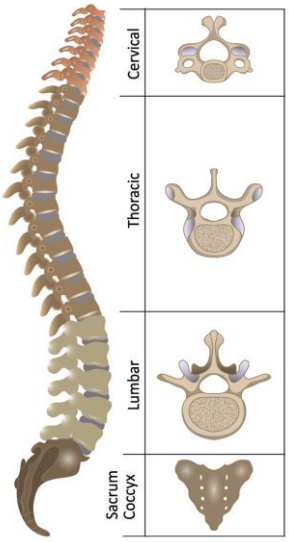

<u>The curvatures of the vertebral column</u>

1-Kyphosis (Thoracic curvature) .

2-Lordosis (Lumber curvature) .

3-Scoliosis (side curvature) .

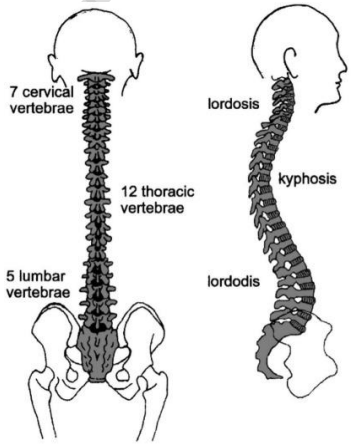

JOINTS

Definition of Joint:
It is the site of meeting of two or more bones.

Types of Joints: There are 3 types of joints according to the

nature of the connecting tissues and Connection Movement .

1-Fibrous joints	**2-Cartilaginous joints**	**3-Synovial joints**
1.The bones connected by fibrous tissue	1. The bones connected by cartilaginous tissue.	1.The bones are separated by a joint cavity that is surrounded by a fibrous capsule & synovial membrane.
2.are fixed joints (not movable)	2. may allow slight movements (slightly movable).	2.are freely movable joints
3. sutures of the skull	3. 1st rib and sentrum	3. knee joint

Types of Joints:

***Hinge-** A hinge joint allows extension . (Elbow, Knee)

***Ball and Socket-** A ball and socket joint allows for radial movement in almost any direction. (Hip, Shoulder)

***Gliding-** plane joint bones slide past each other. Mid-carpal and mid- tarsal joints are gliding joints. (Hands, Feet)

Saddle- allowing a wide range of movement. (Thumb)

* **Pivot joint :** between C1 & C2

* **Condyloid joint :** between radius and carpal bones

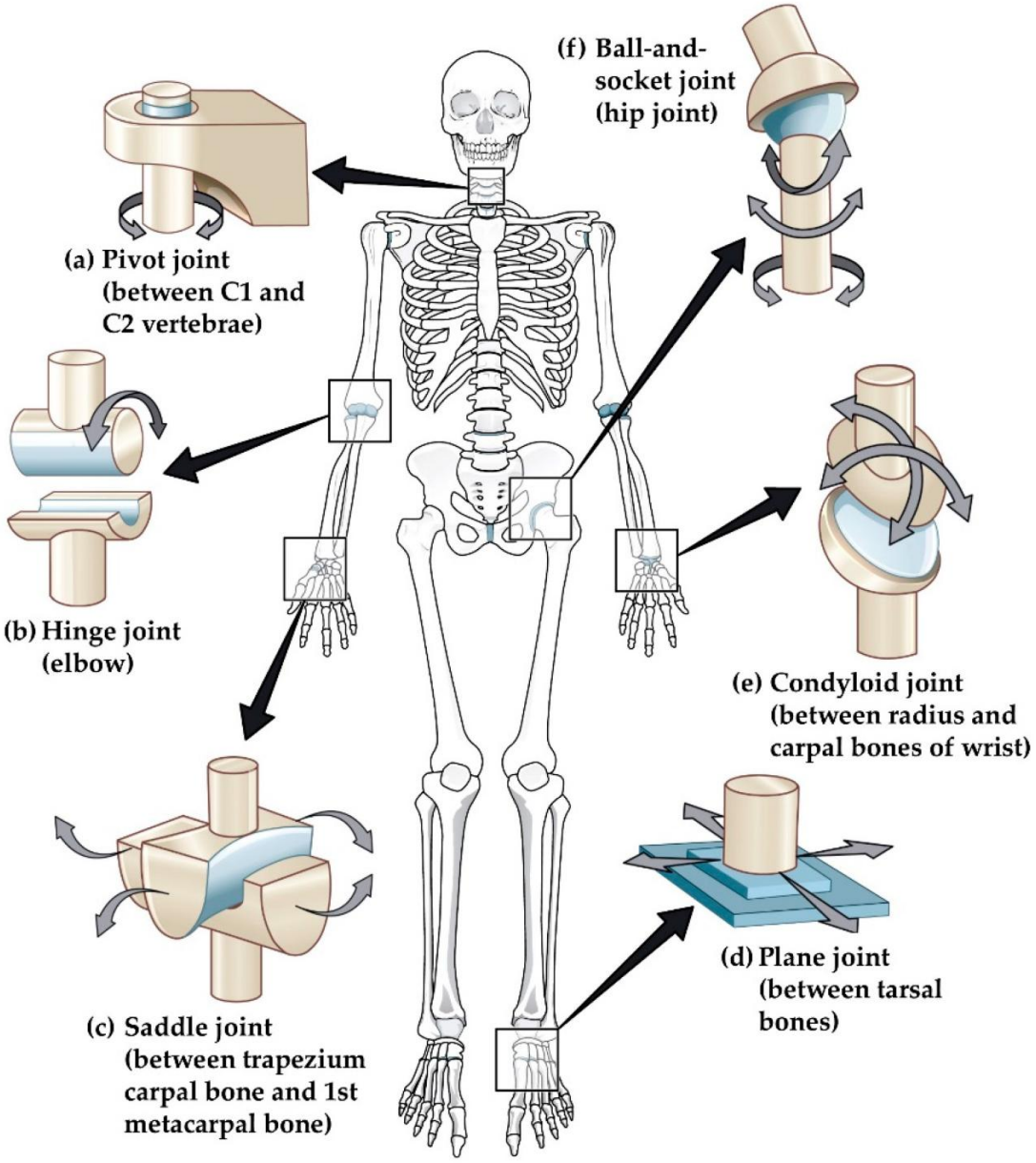
(f) Ball-and-socket joint (hip joint)
(a) Pivot joint (between C1 and C2 vertebrae)
(b) Hinge joint (elbow)
(e) Condyloid joint (between radius and carpal bones of wrist)
(d) Plane joint (between tarsal bones)
(c) Saddle joint (between trapezium carpal bone and 1st metacarpal bone)

Muscular system

It is about 40% from body weight ,its consist :

1-Skeletal muscles : it's the muscles that cover the skeleton system , its control by central nervous system and for that called voluntary muscles , also because its function called sport exercise .

2- Visceral muscles:

These muscles inter in the structures of the internal organs and the blood vessels . They are involuntary type , and there are two kind ;

1-cardiac muscles.

2-smooth muscles.

<u>Muscles of the head, face and neck:</u>

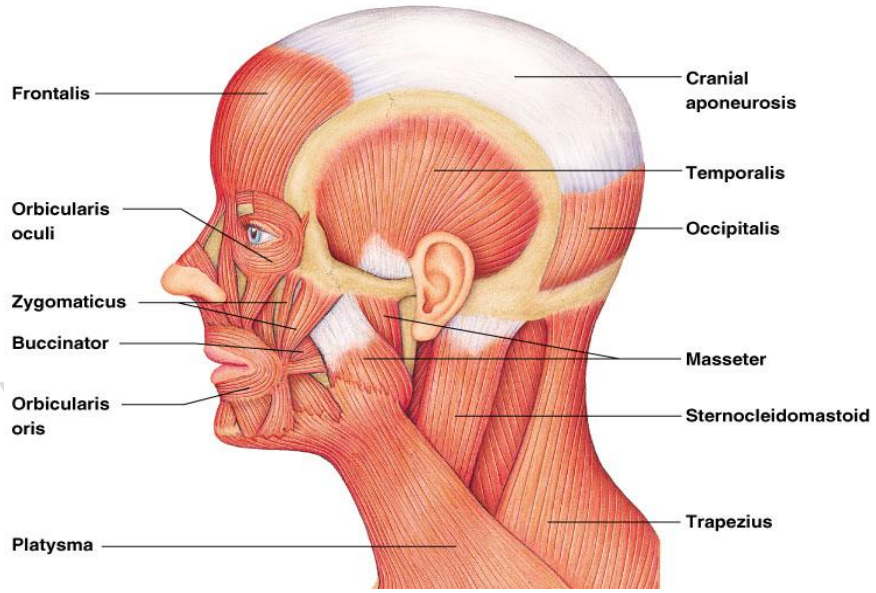

1. Muscles of the **Head: Frontalis /temporalis / occipitalis**
2. Muscles of the **Face: orbicularis occuli / zygomaticus / orbicularis oris / buccinators**
3. Muscles of the **Neck: masseter / sternocleidomastoid / trapizius / platysma**

4.Muscles of the back : latissimus dorsi / external oblique

5. Muscles of the chest : pectoralis major / rectus abdominus / external oblique

6.Muscles of the shoulder : deltoid / teres minor /teres major

7..Muscles of the upper arm: biceps brachii /triceps brachii

8.Muscles of the forearm: brachioradialis / flexor digitorum superfacialis

9.Muscle of pelvis :/gluteus maximus / gluteus medius

10. Muscles of the thigh:sarturius / rectus femoris

11. Muscles of the legs: tibialia anterior / gasterocnemius

12. Muscles of the foot .:extensor digitorum

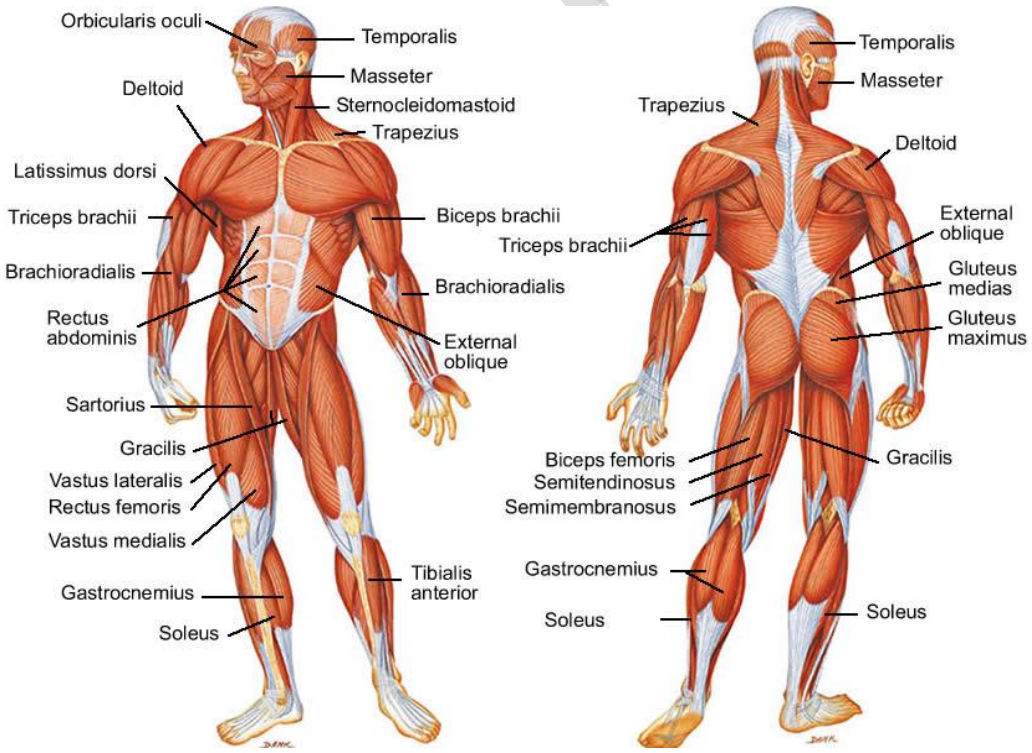

Anatomy of Digestive system

The digestive tract is composed of the alimentary canal together accessory glands and organs.

The **alimentary canal:** is a continuous tube stretching from the mouth to the anus.

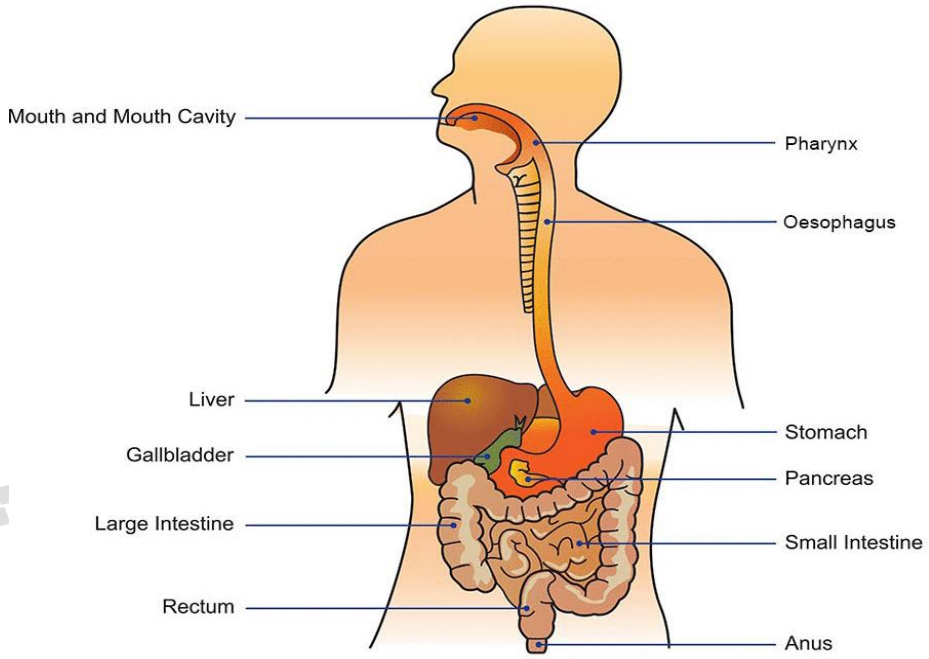

Digestive system is divided in to :

1-Digestive canal (**alimentary canal**) :

Which consist from { mouth, pharynx ,esophageal ,stomach ,small intestine ,large intestine ,rectum and anal canal } .

2-Aditional digestive parts:

1-Salivary gland. (a-parotid gland . b-submandibular gland c-sublingual gland).

2-liver. 3-Gall bladder. 4-Pancreas :

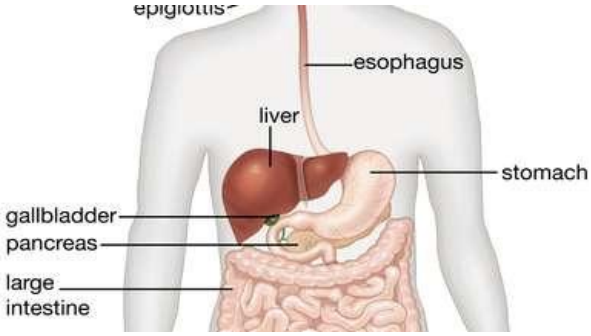

Mouth (Buccal Cavity, Oral Cavity) : bordered above by **hard** and **soft Palate** forms partition between mouth and nasal passages**.**

***Tongue :**lines ventral border of mouth cavity is skeletal muscle covered with mucous membrane contains taste buds.

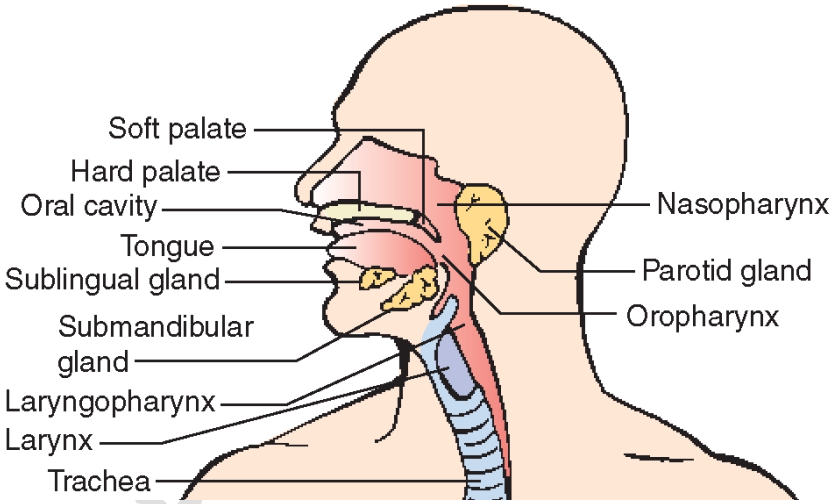

*** Teeth :** two types:

-deciduous (baby teeth) (20) begin at 6 months ; shed 6-13 yrs

-permanent teeth (32).

each tooth has : **=crown** (above gum)

= neck is where crown , gum and root meet

= root (below gum)

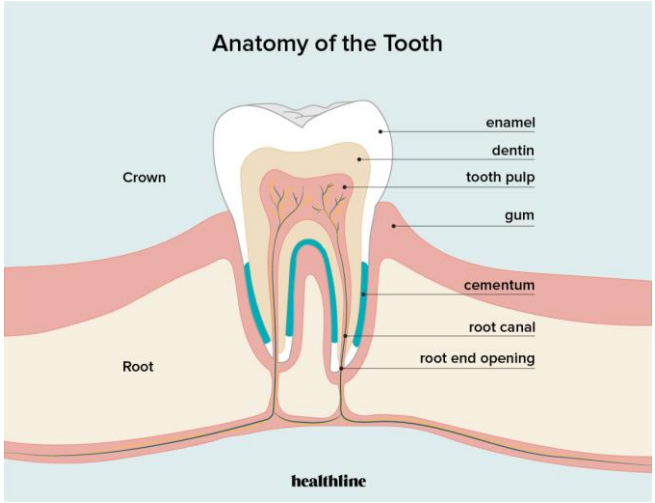

kinds of teeth modified for specific functions:

- **incisors** – 4+4; cut, knip.
- **canines** – 2+2; holding onto prey.
- **premolars** – 4+4; cutting, crushing.
- **molars** – 6+6; chewing, grinding, crushing

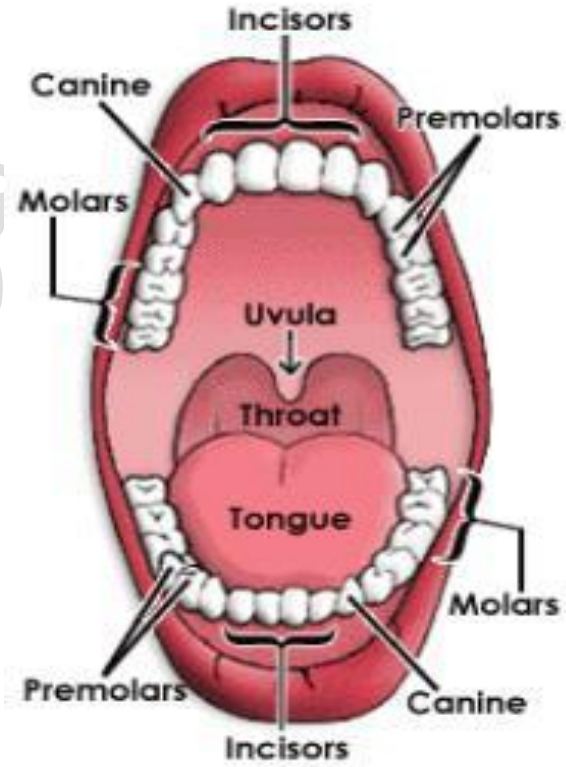

***Salivary Glands :** 3 Pairs of **salivary glands**: sublingual , submandibular , parotid

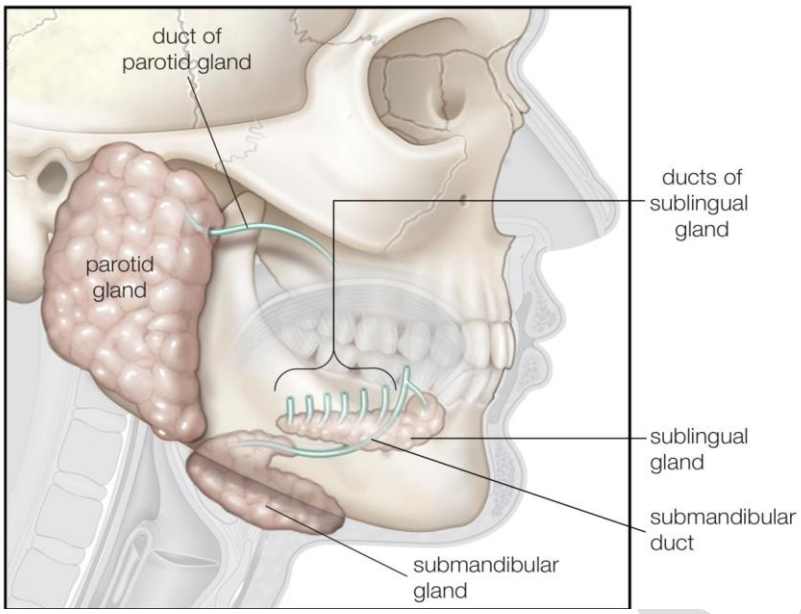

***Pharynx**: (throat).connect the nasal and oral cavities with the larynx and esophagus it has three parts

Nasopharynx oropharynx larengopharynx .

It's function is Swallowing moves the food mass, or bolus, from the mouth into the pharynx.

***Esophagus:** collapsible tube ~ 25” cm long extends from pharynx to stomach gets food through

thorax to abdominal cavity posterior to trachea and heart.

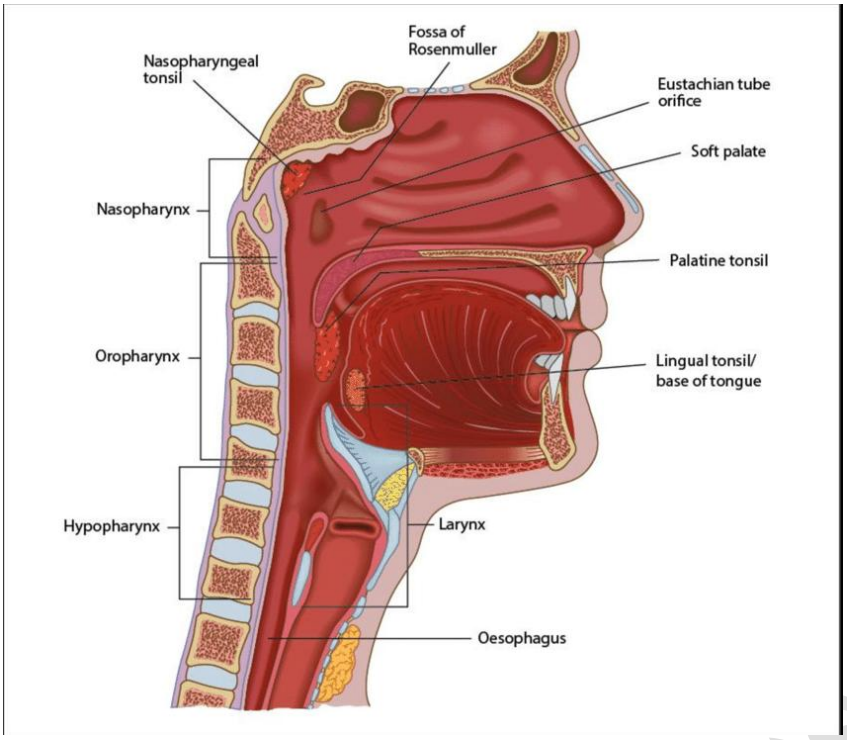

The stomach :is a muscular organ and the widest part of the gastro intestinal tract .It lies in epigastric region , between the esophagus and the small intestine . Empty stomach is J-shaped

The stomach consist of :

Cardiac orifice **2. Fundus** **3. Body** **4. Pylorius** and **pyloric** orifice •

5.**two** curvature **greater** and **lesser** curvature .

Stomach

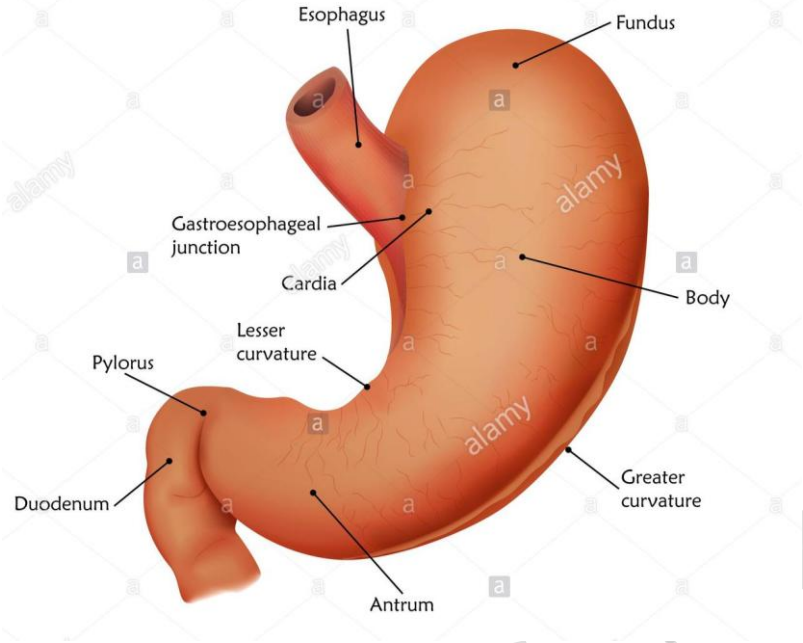

Anatomy of Digestive system(part2)

Liver : Is the largest gland and the largest visceral organ in the body .It is a reddish brown color , a human liver normally weight **1.44-1.66 kg** and is a soft organs . It lies in the right upper quadrant of the abdomen immediately beneath the diaphragm at right of the stomach. (right hypochondrium region).

It is consist of two lobes right(large) and left Lobe (small) .

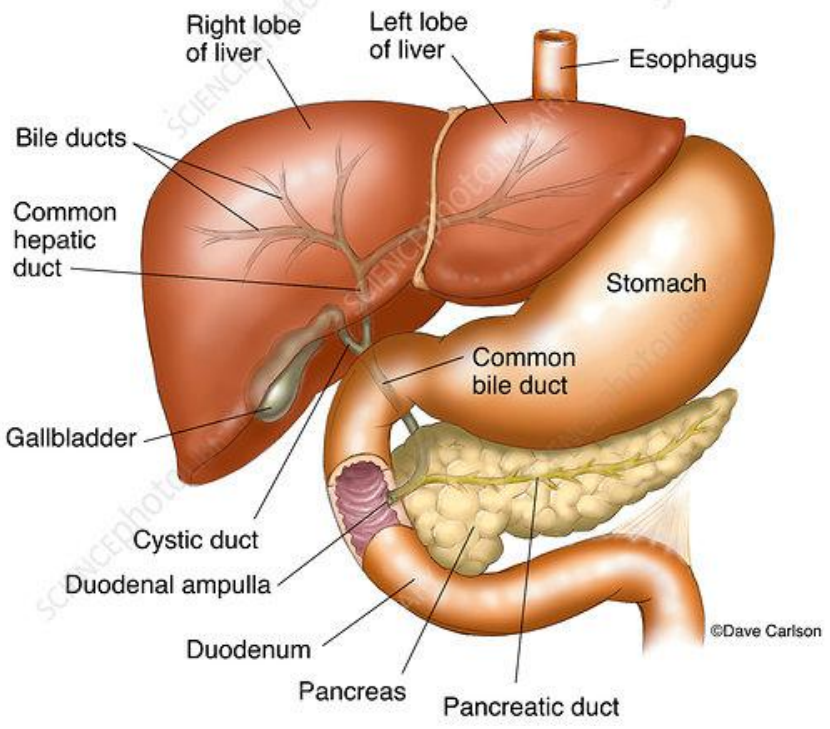

<u>Functions of the liver</u> :

1-production of the bile salt .

2-excretion of the bile secretion .

3-Removel some drugs and hormones and poisoning .

4-Storages some vitamins (A,B12,D,E, K) and some material like (ferrous , copper) .

5-Obsorption the damage of the RBC,WBC and some bacteria .

***Gallbladder:** It is appear-shape sac lying on the inferior surface at the right lobe of the liver.

Function of the gall bladder :

1-Storage of the bile .

2-Increase the concentration of the bile .

3-Execretion of the bile on need .

***Pancreas:** Pancreas both endocrine and exocrine

*Endocrine: **pancreatic islets**. Produce insulin, glucose

*Exocrine: form **lobules** separated by septa, produce digestive enzymes.

Anatomical position : - Epigastric - left upper hypochondrium region.

Consist of . **Head**, **body** and **tail**

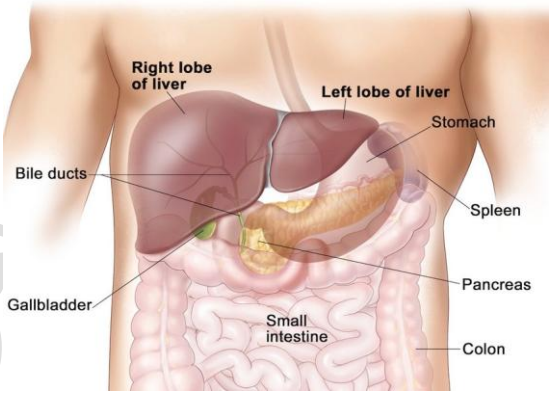

***Small Intestine:** It is tubular organ that extend from pyloric to the beginning of the large intestine longest part of alimentary canal: 3 divisions:

a)Duodenum ~20-25 cm. long 5 cm. in diameter ,drains pyloric stomach receives ducts from gall bladder and pancreas

b) Jejunum ~2.5- 3m long . central portion , mostly in umbilical region, rich blood supply , most digestion and absorption occurs here, absorbs most nutrients , water & salts**.**

c)ileum ~3-4 **m.** mainly in hypogastric region, joins to caecum of large intestine, absorbs and reclaims bile, salts and some additional nutrients.

*The intestinal mucosa also contains small finger-like projections = **villi**~1mm tall each villus contains absorptive epithelial cells.

(villi "functional units" of the digestive system).

Ileocecal valve allows material to move from SI (small intestine) to LI (large intestine). So that valve-like sphincter separates small from large intestine = **ileocecal valve.

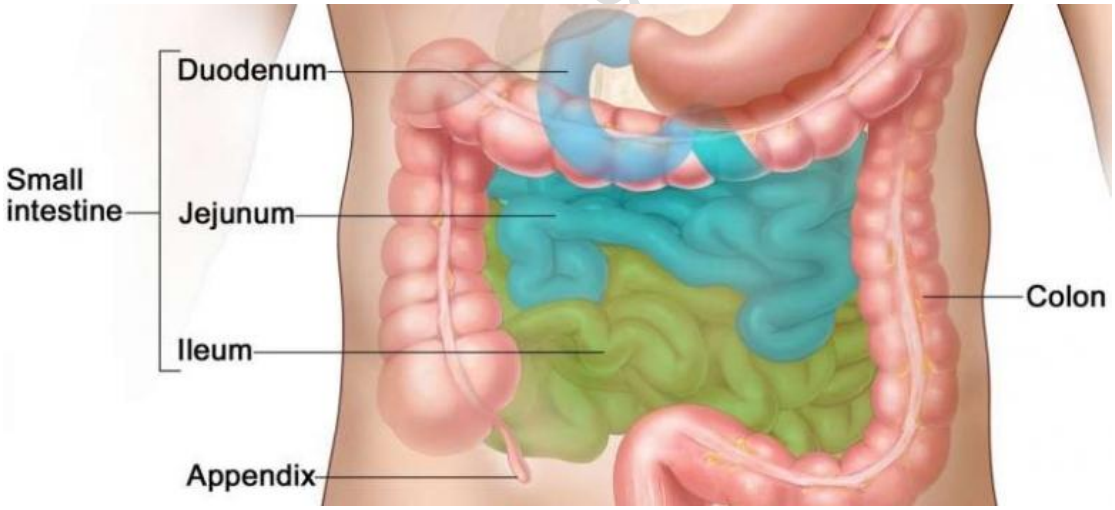

*** Large Intestine:** 1.5 m. long and 6 cm. diameter and consist of :

1.Cecum :

2**.appendix** ! ~3.5” (9cm) long.

3.ascending colon

4.hepatic flexure.

5.transverse colon

6.splenic flexure

7.descending colon

8.sigmoid colon

9.rectum: last 7-8” cm, ends at **anus**

held shut by two **anal sphincters**:

internal anal sphincter of smooth muscle

external anal sphincter of skeletal muscle

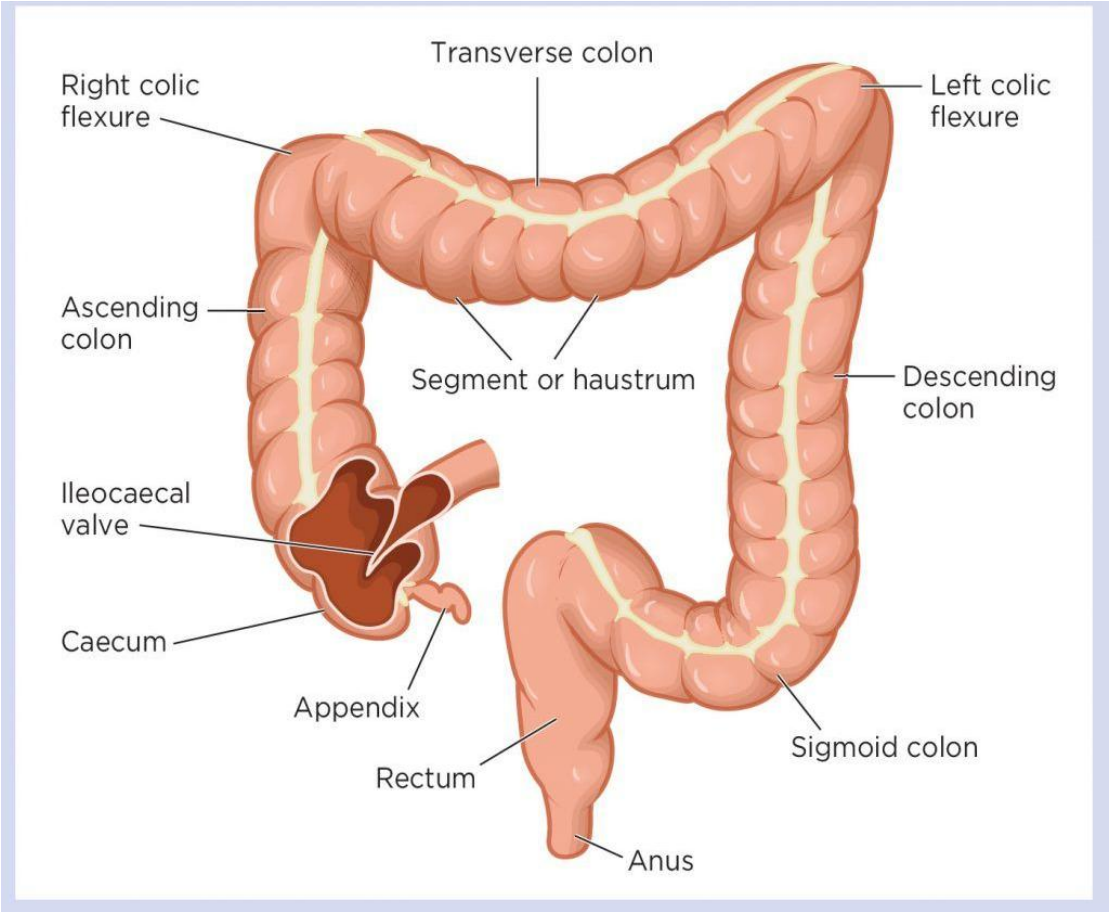

Anatomy of Nervous system

Its divided into :

*A-Somatic N.S. :*Which divided into two main parts:

I-Central N.S. **II- Peripheral N.S.**

B -Autonomic nervous system:

*** sympathetic**

*** parasympathetic**

****

I-Central N.S.: Which consist from:

*Cerebellum :Which consist from (3) cereballar peduncles (superior ,middle, inferior).

involved in *movement* control, coordination, posture and control all the muscles contraction of the body .

I-Central N.S.: Which consist from:

1-*Brain* : The brain is one of the largest and most complex organs in the human body. It is made up of more than 100 billion nerves that communicate in trillions of connections called synapses.

The brain is made up of many specialized areas that work together:

• The cortex is the outermost layer of brain cells. Thinking and voluntary movements begin in the cortex.

• The brain stem is between the spinal cord and the rest of the brain. Basic functions like breathing and sleep are controlled here.

• The basal ganglia are a cluster of structures in the center of the brain. The basal ganglia coordinate messages between multiple other brain areas.

• The cerebellum is at the base and the back of the brain. The cerebellum is responsible for coordination and balance.

The brain is surrounded by a layer of tissue called the meninges. The skull (cranium) helps protect the brain from injury.

Brain consist of the following parts :

*Cerebrum: is the largest part of the brain and is composed of right and left hemispheres. It performs higher functions like interpreting touch, vision and hearing, as well as speech, reasoning, emotions, learning, and fine control of movement.

it is divided into several lobes

1.The frontal lobes are responsible for problem solving and judgment and motor function

2.The parietal lobes manage sensation, handwriting, and body position

3.The temporal lobes are involved with memory and hearing

4.The occipital lobes contain the brain's visual processing system

****Cerebellum: is located under the cerebrum. Its function is to coordinate muscle movements, maintain posture, and balance.**

*****Brainstem: acts as a relay center connecting the cerebrum and cerebellum to the spinal cord. It performs many automatic functions such as breathing, heart rate, body temperature, wake and sleep cycles, digestion, sneezing, coughing, vomiting, and swallowing.**

1.mid brain . **2.Pons .**

3.medulla oblongata.(Which continue to pass through foramen magnum to the beginning of the spinal cord).

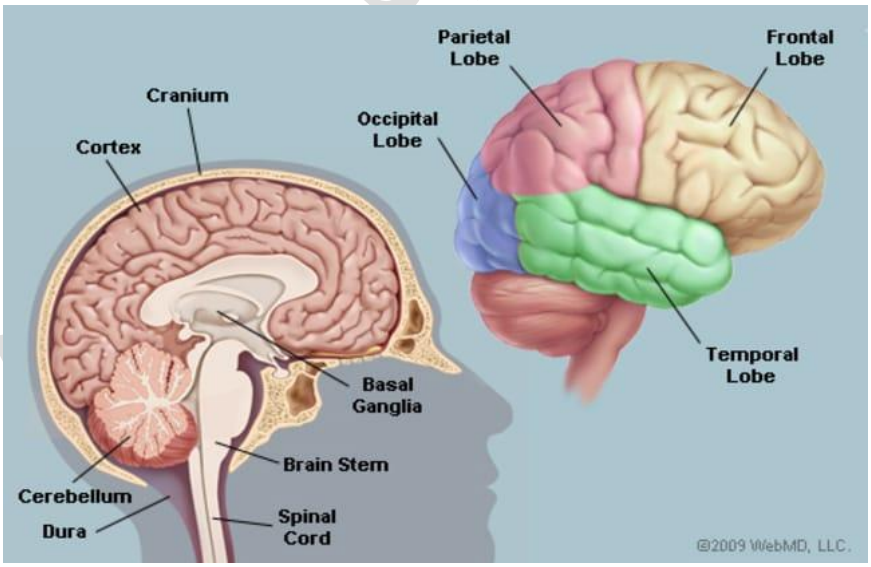

2-*Spinal cord* : is a tubular bundle of nervous tissue and supporting cells that

extends from the brainstem(medulla oblongata) to the lumbar vertebrae.

Together, the spinal cord and the brain form the central nervous system.

The spinal cord arises cranially as a continuation of the medulla oblongata (part of the brainstem). It then travels inferiorly within the vertebral canal, surrounded by the spinal meninges containing cerebrospinal fluid.

*At the L2 vertebral level the spinal cord tapers off, forming the conus medullaris.

As a result of the termination of the spinal cord at L2, it occupies around two thirds of the vertebral canal.

*It is consider the center of SC Reflexes and communication between the brain and body parts . It consist from grey matter (cells) and white matter (fibers).

* Extends from medulla to L2 in adults 16 to 18 in. long about 0.5 in. diameter.

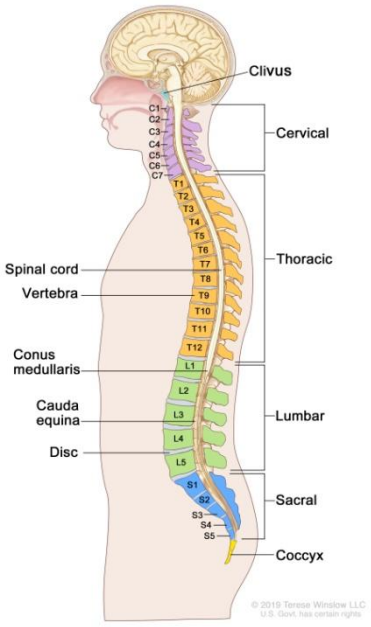

3-Meninges:==Dura matter ==Arachnoids matter. ==Pia matter.

Three layers of membranes known as meninges protect the brain and spinal cord.

The delicate inner layer is the pia mater.

The middle layer is the arachnoid, a web-like structure filled with fluid that cushions the brain.

The tough outer layer is called the dura mater.

***C.S.F(cerebro-spinal fluid):**

The fluid that present in the subarachnoid space , its colorless fluid, similar to the lymphatic fluid in their continence and function .

It's used for the diagnosis some disease through L.P.(lumber puncture) .

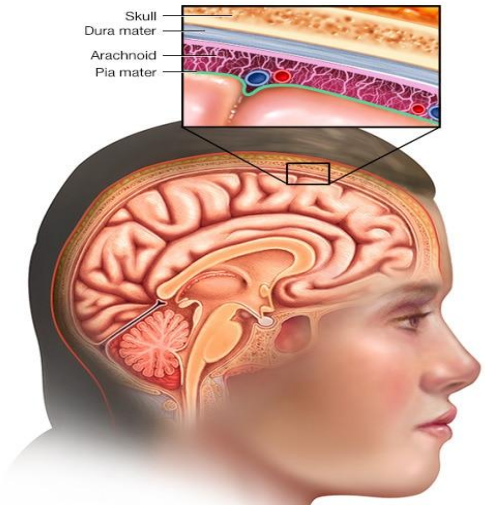

II- Peripheral N.S. Consist from :

1. cranial nerves (12)pairs (which supply the head and neck except vagus nerve(10) supply the thoracic and abdomen structures).

1. **Olfactory / (**smell)
2. **Optic nerve** / (transforms information about vision)
3. **Oculomoter nerve** / (rotating eyeball)
4. **Trochlear** / (handling and turning the eye).
5. **Trigeminal / (**sensory functions related to nose, eyes, tongue and teeth).
6. **Abducent / (** turning eye laterally).
7. **Facial / (**different types of facial expressions**).**
8. **Vestibulocochlear** / (balance of head and hearing)
9. **Glossopharyngeal / (**swallowing food).
10. **Vagus** /(pharynx, larynx, esophagus, trachea, bronchi, some portion of heart and palate).
11. **Spinal accessory nerve** / (spinal cord)
12. **Hypoglossal nerve** / (muscles of tongue)

2.Spinal nerves: which are 31 pairs

-cervical (8) pairs

-thoracic (12) pairs

-lumbar (5) pairs

-sacral (5) pairs

-coccygeal (1) pair

The spinal nerves that arise from the end of the spinal cord are bundled together, forming a structure known as the cauda equina

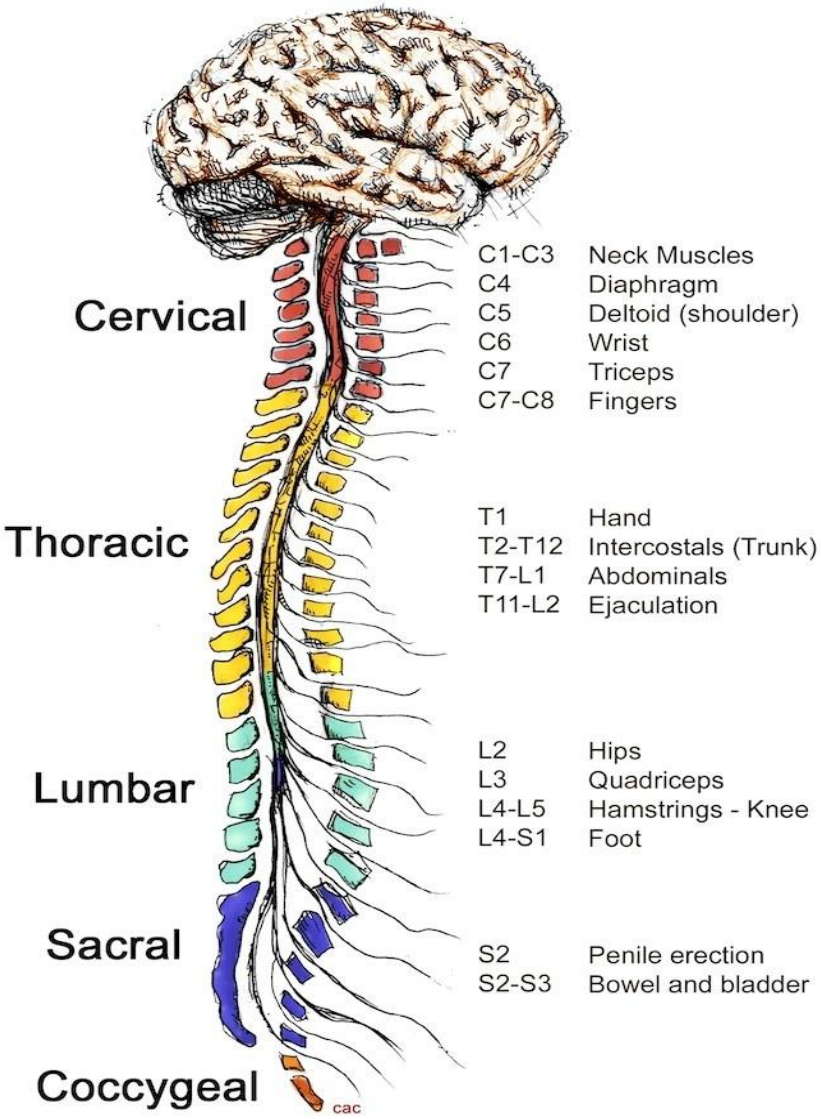

*** Autonomic nervous system**:

It is involuntary" system which regulates functions of internal organs, e.g., heart, intestines. It is divided into sympathetic & parasympathetic

i) sympathetic:

- expends energy ("fight or flight", need in emergency)
- increase heart rate and breathing
- gets glucose and oxygen to muscles and brain
- decreases digestion, decrease mucus flow.

- Neurotransmitter is Nor epinephrine.

ii) parasympathetic:

- conserves energy (“rest and digest”)

- decrease heart rate and breathing.

- stimulation of secretion of saliva, stimulates the processes of urination

- increase digestion, increase mucous flow.

- Neurotransmitter is Acetylcholine.

**A neuron is a nerve cell that is the basic building block of the nervous system (functional unit of the nervous system).

Consist of (**the dendrites, the cell body and the axon)**

Neurons

are cells within the nervous system that transmit information to other nerve cells, muscle, or gland cells. Most neurons have a cell body, an axon, and dendrites.

The cell body contains the nucleus and cytoplasm. The axon extends from the cell body and often gives rise to many smaller branches before ending at nerve terminals.

Dendrites extend from the neuron cell body and receive messages from other neurons.

Synapses are the contact points where one neuron communicates with another. The dendrites are covered with synapses formed by the ends of axons from other neurons.

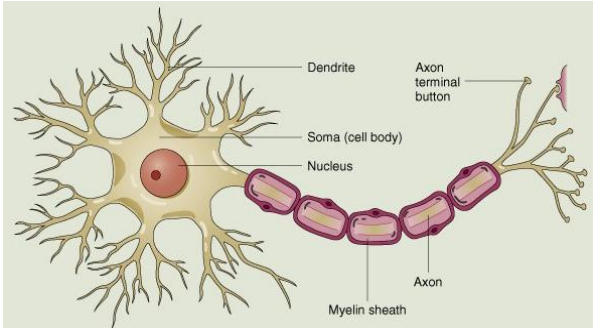
Dendrite
Axon terminal button
Soma (cell body)
Nucleus
Axon
Myelin sheath

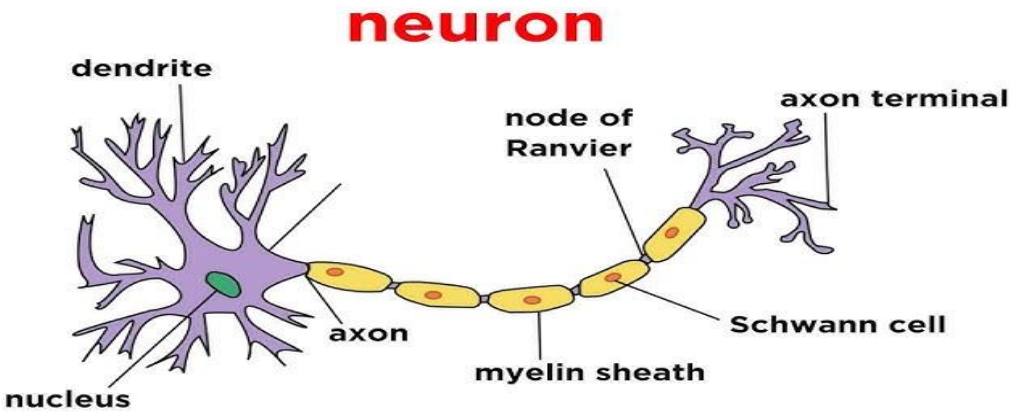
neuron
dendrite
node of Ranvier
axon terminal
axon
Schwann cell
myelin sheath
nucleus

Anatomy of Urinary system

General Functions of Urinary System:

1.removal of **metabolic wastes** & **toxins.**

2.elimination of excess nutrients & excess hormones

3.helps to regulate **blood volume** & **pressure**

4.regulation of **electrolytes** & body **pH**

5.aids in **calcium absorption**.

Main Organs of Urinary System:

***kidneys** – clean and filter blood.

***ureters** – tubes that take urine to bladder

***bladder** – stores urine until eliminated

***urethra** – removes urine from body

1. **kidneys :** The kidneys are the primary organs of the urinary system. The kidneys

   are the organs that filter the blood, remove the wastes, and excrete the wastes in the urine.

They are the organs that perform the functions of the urinary system. The other

components are accessory structures to eliminate the urine from the body.

The paired kidneys are located dorsal body wall at level of the lower ribs

between the twelfth thoracic and third lumbar vertebrae, one on each side of

the vertebral column. The right kidney usually is slightly lower than the left because

the liver displaces it downward.

The kidneys, protected by the lower ribs, lie in shallow depressions against

the posterior abdominal wall and behind the parietal peritoneum.

Each kidney is held in place by connective tissue, called renal fascia, and is

surrounded by a thick layer of adipose tissue, called perirenal fat, which helps to

protect it. In the adult, each kidney is approximately 3 cm thick, 6 cm wide,

and 12 cm long **which consist of :**

***renal capsule:** A tough, fibrous, connective tissue closely envelopes each kidney

and provides support for the soft tissue that is inside.

* **cortex** outer reddish zone of kidney.

* **medulla :** inner brown zone of kidney

The renal medulla consists of
renal pyramids, which appear striated because they contain straight tubular structures and blood vessels.

renal papillae**,** The wide bases of the pyramids are adjacent to the cortex and the pointed ends, are directed toward the center of the kidney.
The cortex and medulla make up the parenchyma

* **Calyces :**calyces converge to form **renal pelvis** which is a large cavity that collects the urine as it is produced. **located at** The central region of the kidney , in the renal sinus, and is continuous with the ureter**.**

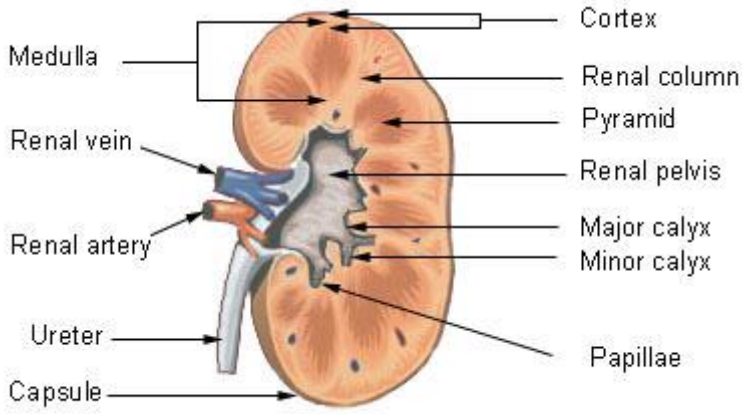

****nephron** = functional units of kidneys …each kidney is composed of over 1 million nephrons. Nephrone consist of the followings:

a. Renal corpuscle //Composed of a glomerulus and the Bowman's capsule

b. Renal tubule **:** the components of the renal tubule are:

- Proximal convoluted tubule (lies in cortex)

- Loop of Henle.(U-shaped and lies in medulla)

- Descending limb of loop of Henle

- Distal convoluted tubule

- Collecting duct system

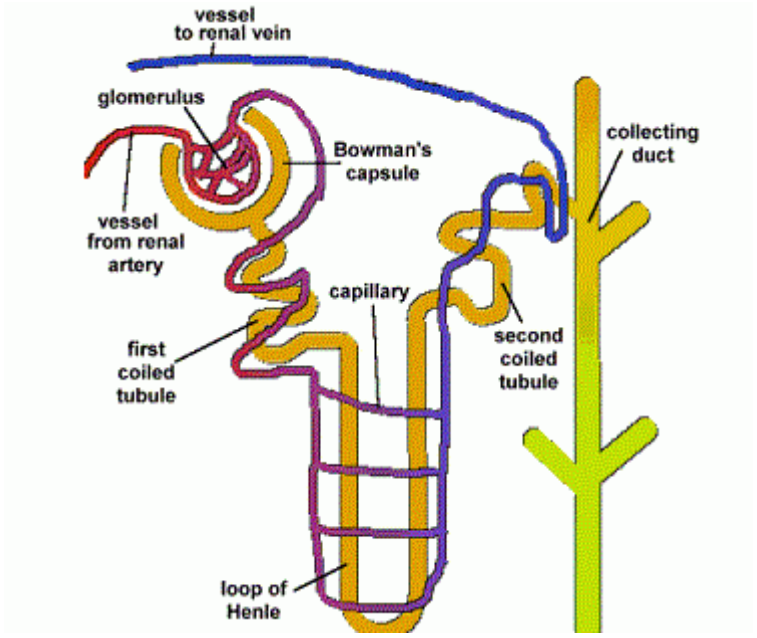

2.ureters : Each ureter is a small tube, about 25 cm long, that carries urine from

the renal pelvis to the urinary bladder. It descends from the renal pelvis, along

the posterior abdominal wall, which is behind the parietal peritoneum, and enters the

urinary bladder on the posterior inferior surface.

The wall of the ureter consists of three layers.

* The outer layer, the fibrous coat, is a supporting layer of fibrous connective tissue.

**The middle layer, the muscular coat, consists of the inner circular and outer

longitudinal smooth muscle. The main function of this layer is peristalsis: to propel the urine.

***The inner layer, the mucosa, is transitional epithelium that is continuous with the

lining of the renal pelvis and the urinary bladder. This layer secretes mucus, which

coats and protects the surface of the cells.

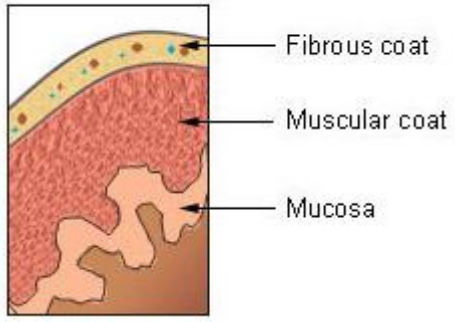

3.Urinary Bladder : small, size like walnut when empty The urinary bladder is a

temporary storage reservoir for urine. It is located in the pelvic cavity, posterior to

the symphysis pubis, and below the parietal peritoneum.

The size and shape of the urinary bladder varies with the amount of urine it contains and with the pressure it receives from surrounding organs.

The urinary bladder consists of three layers.

*The inner lining of the urinary bladder is a mucous membrane of transitional

epithelium that is continuous with that in the ureter. When the bladder is empty,

the mucosa has numerous folds called rugae. The rugae and transitional epithelium

allow the bladder to expand as it fills.

**The second layer in the walls is the sub mucosa, which supports the mucous

membrane. It is composed of connective tissue with elastic fibers.

***The next layer is the muscularis, which is composed of smooth muscle.

central muscular layer under voluntary central and contrast in

response to certain reflexes

*the bladder increase to the size of soft ball when full.normally it

can hold about (360-480cc).

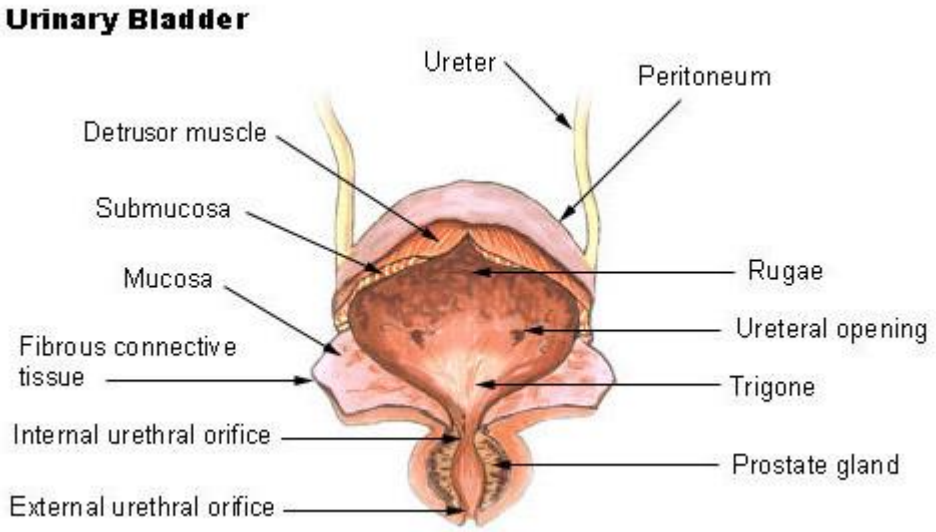

4. urethra: The final passageway for the flow of urine is the urethra, a thin-walled

tube that conveys urine from the floor of the urinary bladder to the outside.

The opening to the outside is the external urethral orifice. The mucosal lining of the

urethra is transitional epithelium. The wall also contains smooth muscle fibers and is

supported by connective tissue.

The internal urethral sphincter surrounds the beginning of the urethra, where it

leaves the urinary bladder. This sphincter is smooth (involuntary) muscle.

Another sphincter, the external urethral sphincter, is skeletal (voluntary) muscle and

encircles the urethra where it goes through the pelvic floor. These two sphincters

control the flow of urine through the urethra.

Differences between male and female urethra

male: double function:

- rid body of urine
- release of seminal fluid during orgasm
- it's long about 8 inches

female: single function:

- rids body of urine
- Shorter , more prone to UTI's.
- It's long about 1.5 inches

Reproductive (genital) system :

Male genital system :

A-Internal organs:

1-Testis . 2-Epididymis . 3-Vasdegferens. 4-Seminal vesicle .

5-Ejaculatory . 6-Prostate. 7-Cowpets gland .

B-External organs :

1-Scrotum . 2-Penis .

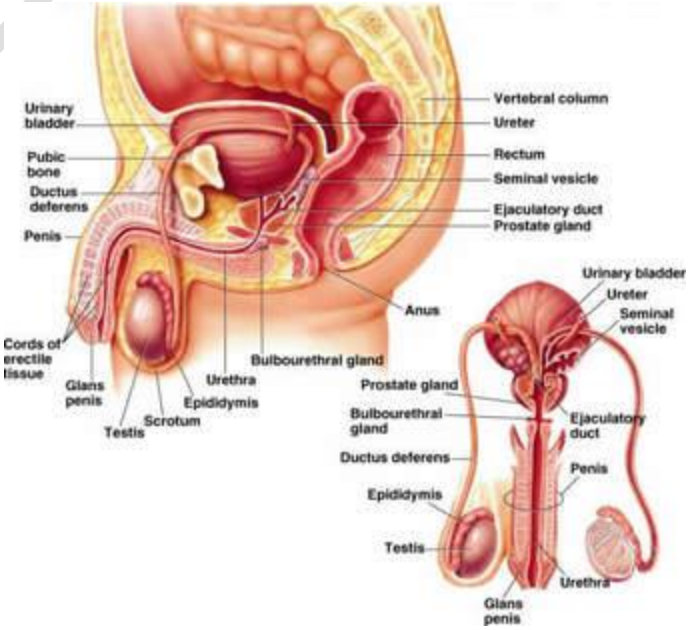

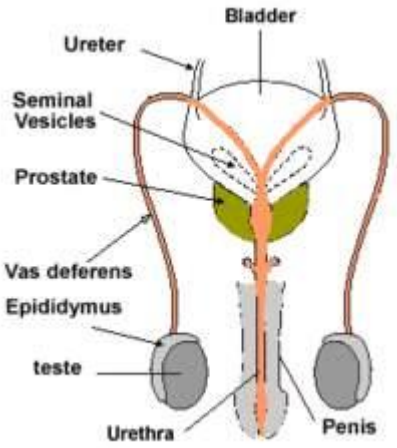

Female genital system :

A-External organs :

1-Pubic area . 2-Labia major . 3- Labia minor .

4-Clitoris . 5-Partholine gland . 6-Vagina .

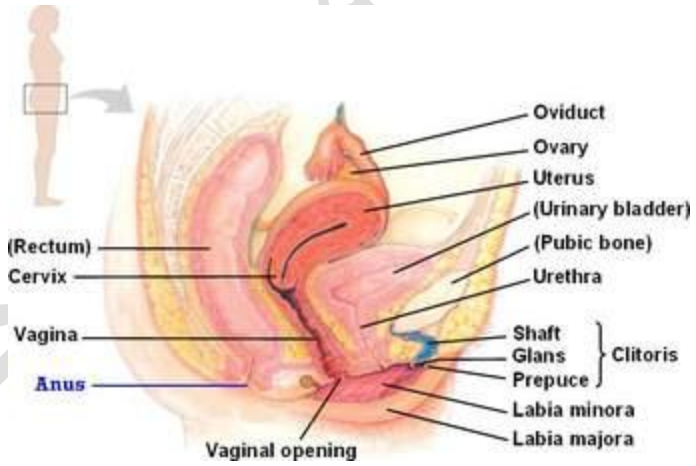

B- Internal organs*:*

1-Vagina . 2-Uterus . 3-Fallopian (uterine) tube . 4-Ovary

Anatomy of Respiratory system

General Functions of Respiratory System:

1. O2 and CO2 exchange between blood and air
2. speech and vocalization
3. sense of smell
4. helps control acid base balance of body
5. breathing movements help promote blood and lymph flow

Main Organs of the Respiratory System:

*nose *pharynx *larynx *trachea *primary bronchi

*lungs *bronchioles *alveoli/respiratory membrane

These organs can also be subdivided into:

*** upper respiratory tract:** nose! pharynx! larynx

****lower respiratory tract:** respiratory organs of the thorax , the lower respiratory tract fills most of the thorax.

*Parts of the upper Respiratory Tract:

1. **Nose:** separated from mouth by hard and soft palate .

2.Paranasal Sinuses: The paranasal sinuses are air-filled spaces located within the bones of the skull and facial bones. They are centered on the nasal cavity and have various

functions, including lightening the weight of the head.

Four bones of the skull contain paired air spaces called the paranasal sinuses - frontal, ethmoidal , sphenoidal, maxillary

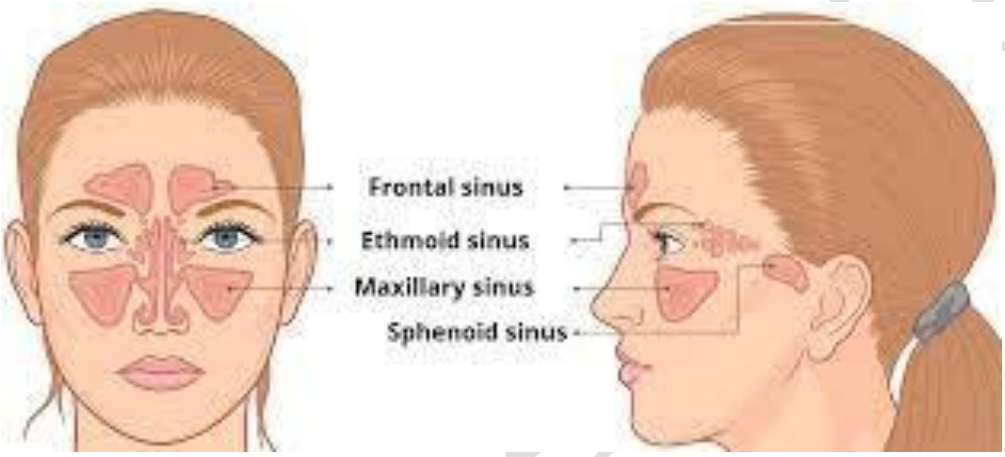

Pharynx (throat): from base of skull to junction with esophagus and trachea 5cm. long .

** **Pharynx divided into three regions:**

a. **Nasopharynx :**behind nose to level of soft palate includes tonsils (adenoids)

b. **Oropharynx :**behind mouth from soft palate to level of hyoid bone

c. **Laryngopharynx :** from hyoid bone to esophagus / larynx.

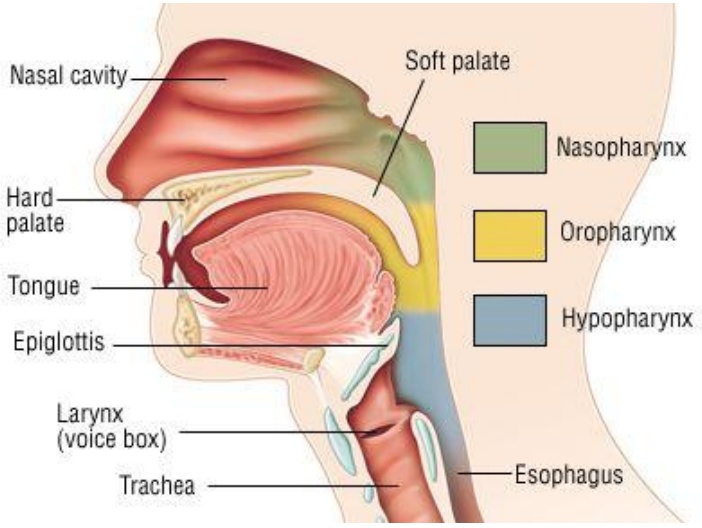

The larynx: (voice box):

it is a short, somewhat cylindrical airway the trachea, at where sound is generated is located in the anterior compartment of the neck, suspended from

the hyoid bone, and spanning between C3 and C6.

It is continuous inferiorly with the trachea, and opens superiorly into the laryngeal

part of the pharynx. It is covered anteriorly by the infra hyoid muscles, and laterally

by the lobes of the thyroid gland. The larynx is also closely related to the major blood

vessels of neck. Posterior to the larynx is the oesophagus.

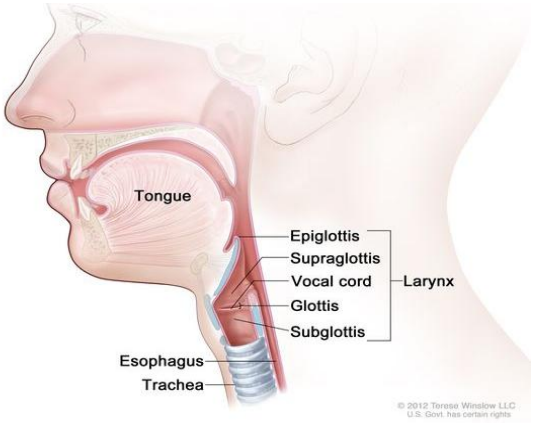

The main functions of larynx are:

1.controls air and food are passed into t proper channels.

2. produce a voice.
3. It conducts air into and out of the trachea while preventing foreign objects from entering.
4. houses the vocal chords.

The larynx is made up of muscles and nine cartilages that
are bound by elastic tissues consisting of ligaments and membranes.
The cartilages include the
epiglottic cartilage and ,**cricoidcartilage** ,**thyroid cartilage**

***thyroid cartilage called Adam's apple largest cartilage of larynx, Testosteron estimulates the growth of the laryngeal prominence so it becomes larger in males than in females = adam's apple.**

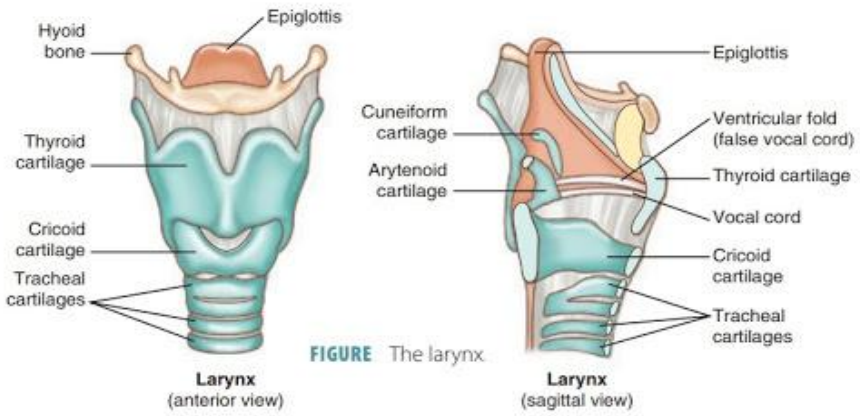

FIGURE The larynx

Lower respiratory tract: Composed of the trachea, the lungs, and all segments of the

bronchial tree (including the alveoli), the organs of the lower respiratory tract are located inside the chest cavity.

.Trachea: Located just below the larynx, the trachea is the main airway to the 1lungs
It ranges from (20-25) mm in diameter and (10-14) cm in length

2.Lungs: Together the lungs form one of the body's largest organs. They're responsible for providing oxygen to capillaries and exhaling carbon dioxide.
two lungs left lung , 2 lobes // right lung , 3 lobes all organs between the

two lungs are located in the mediastinum.

3.Bronchi: The bronchi branch from the trachea into each lung and create the network of intricate passages that supply the lungs with air.
The left bronchi is narrower, longer and more horizontal than the right.

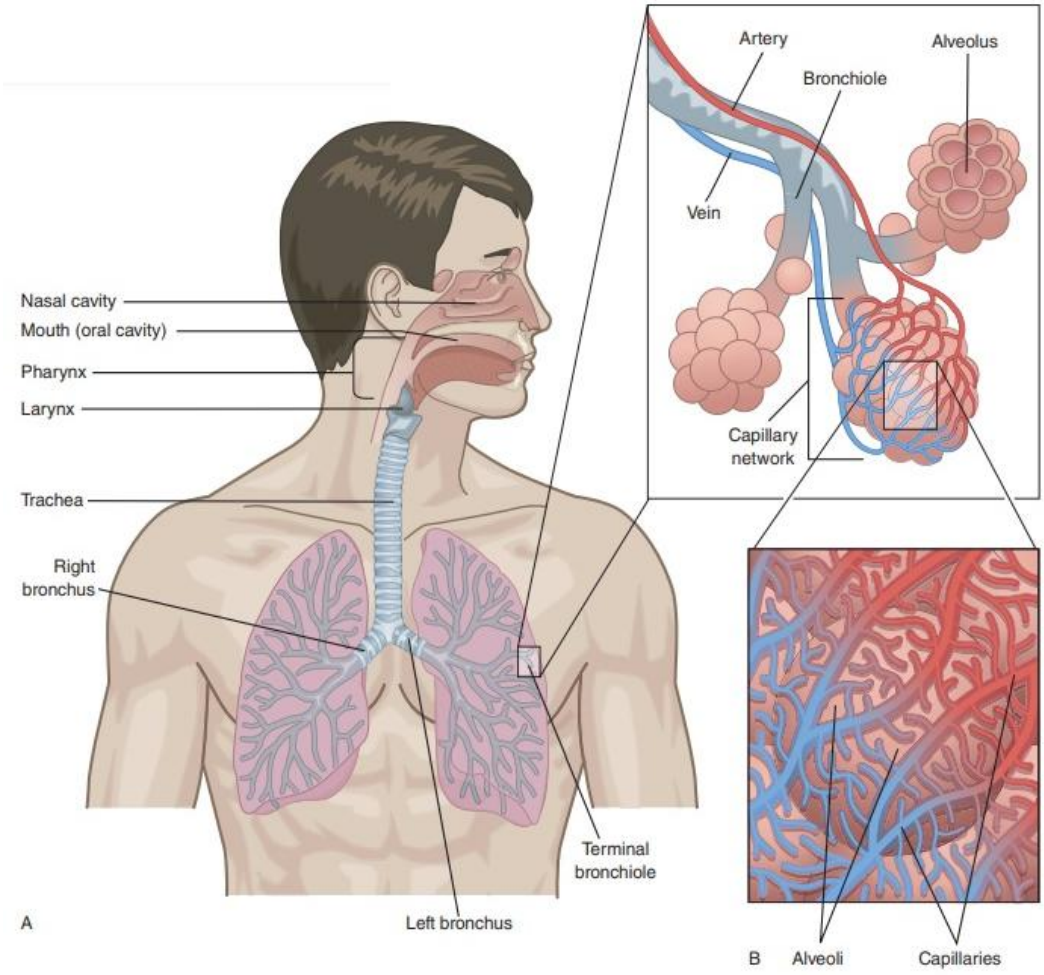

4.Bronchioles: Tertiary bronchi continue to divide and become bronchioles, very narrow tubes, less than (1) millimeter in diameter.

*There is no cartilage within the bronchioles and they lead to alveolar sacs.

5.Alveoli: It is a hollow cavities contained within alveolar sacs (or ducts).

Alveoli have very thin walls which permit the exchange of gases Oxygen and Carbon Dioxide.

There are approximately 3 million alveoli within an average adult lung.

lung alveoli are the “functional units” of the respiratory system.

6.Diaphragm: The diaphragm is a broad band of muscle which sits underneath the lungs, attaching to the lower ribs, sternum and lumbar spine and forming the base of the thoracic cavity

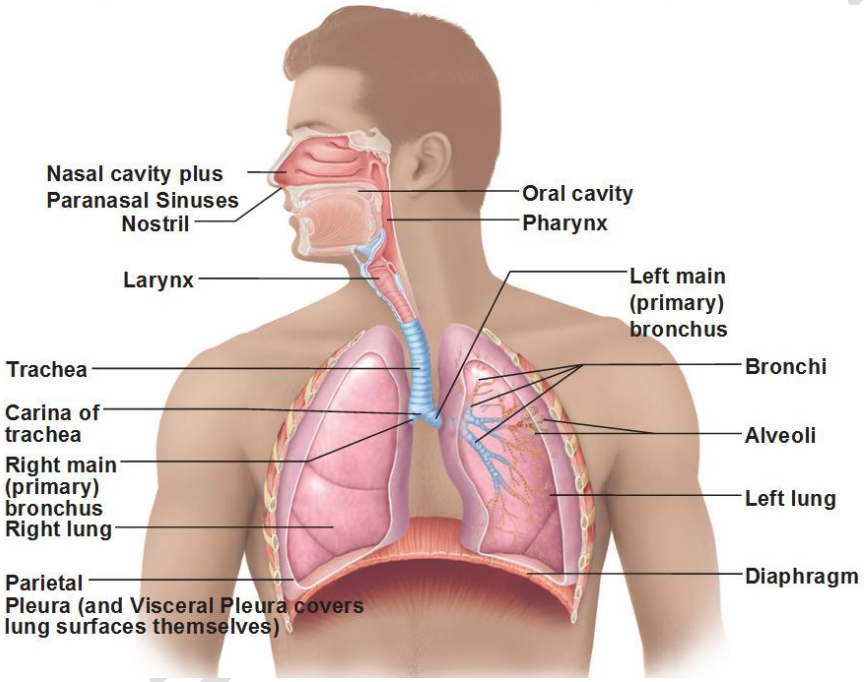

Anatomy of The Cardio vascular system

General Functions of Circulatory System:

a. Transport b. Homeostasis c. Protection

The heart: is one of first organ systems to appear in developing embryo ! heart is beating by 4th week.

Location:

Heart placed in the thoracic cavity

Superior surface of diaphragm Left of the midline

Anterior to the vertebral column, posterior to the sternum

*superior border of heart = **base**

*lower border of heart (=**apex**) lies on diaphragm

heart is enclosed in its own sac, = **pericardium**

Boundary of the Heart: Parasternally

- 2nd left rib
- 3rd right rib
- 6th right rib
- 5th intercostal space (midclavicular line).

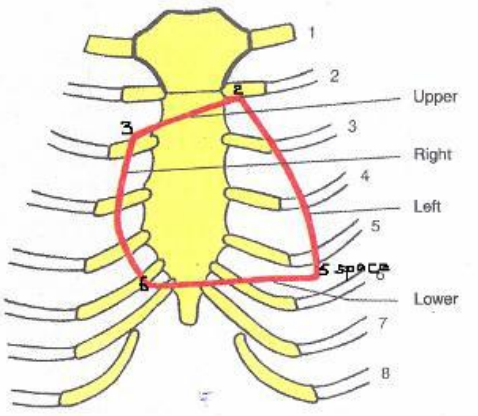

***wall of heart:**

epicardium = visceral pericardium thin & transparent serous tissue

myocardium = cardiac muscle cell most of heart branching

endocardium = delicate layer of endothelial cells continuous with inner lining of blood vessels.

***Heart Chambers:** heart is subdivided into **4 chambers**:

***atriaums** = two upper chambers with auricles smaller, thinner, weaker

***ventricles** = two lower chambers larger, thicker, stronger.

left ventricle much larger and thicker than right ventricle ,left ventricle is at apex of heart.

*Heart Vessels:

There are 4 major vessels attached to heart:

*** 2 arteries** (take blood away from heart):

Aorta - from left ventricle

pulmonary trunk - from right ventricle

** Aortic arch … have important blood vessels:

a. left subclavian artery .

b. left common carotid artery

c. brachiocephalic artery

*** 2 veins** (bring blood back to heart):

(superior **vena cava** & inferior **vena cava**) to right atrium **pulmonary veins**.

****the heart is supplied by coronary arteries which are left and right coronary arteries**

***Heart Valves :**

There are 4 one-way valves that direct flow of blood through the heart in one direction:

1-Pulmonary V.: between right ventricle and pulmonary trunk.

2-Aortic V. : between left ventricle and aorta.

3-Mitral V. : between left atrium and left ventricle .

4-Tricuspid V. : between right atrium and right ventricle.

External Heart: Anterior View

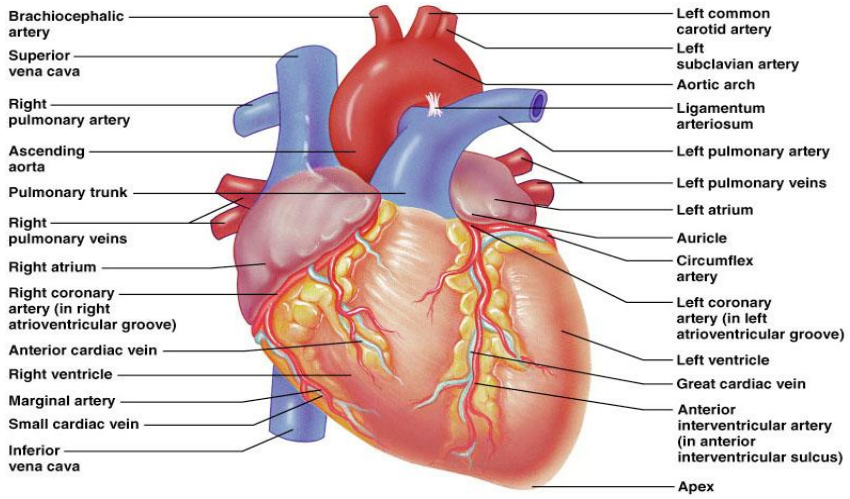

Figure 18.4b

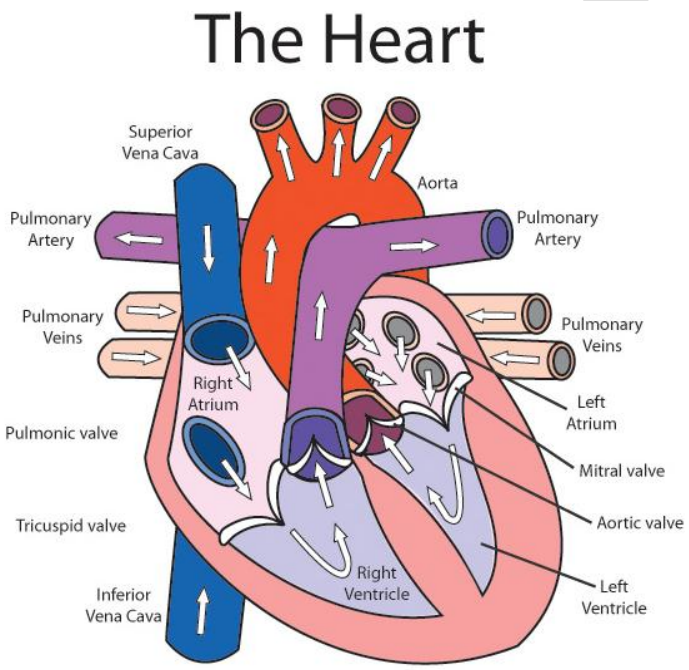

* **Arteries & arterioles:** take blood away from heart to capillaries.

***Capillaries:** actual site of exchange**.**

* **Venules & veins :** bring blood from capillaries back to heart**.**

Comparison between arteries and veins:

Veins	Arteries
1. carry deoxygenated blood (with the exception of pulmonary veins From various parts of the body to the heart..	1.carry oxygenated blood (with the exception of the pulmonary artery from the heart to various parts of the body
2.Thin, elastic muscle layer	2.Thick, elastic muscle layer
3.low pressure of the blood flowing	3.high pressure of the blood flowing
4.Have valves that prevent the blood from flowing in the opposite direction	4.No valves.
5.Closer to the skin (superficial)	5.Deeper in the body.

Pulmonary Circulation

Pulmonary circulation is the movement of blood from the heart to the lungs for oxygenation, then back to the heart again . Oxygen-depleted blood from the body leaves the systemic circulation when it enters the right atrium through the superior and inferior vena cava . The blood is then pumped through the tricuspid valve into the right ventricle. From the right ventricle, blood is pumped through the pulmonary valve and into the pulmonary artery. The pulmonary artery splits into the right and left pulmonary arteries and travel to each lung. At the lungs, the blood travels through capillary beds on the alveoli where respiration occurs

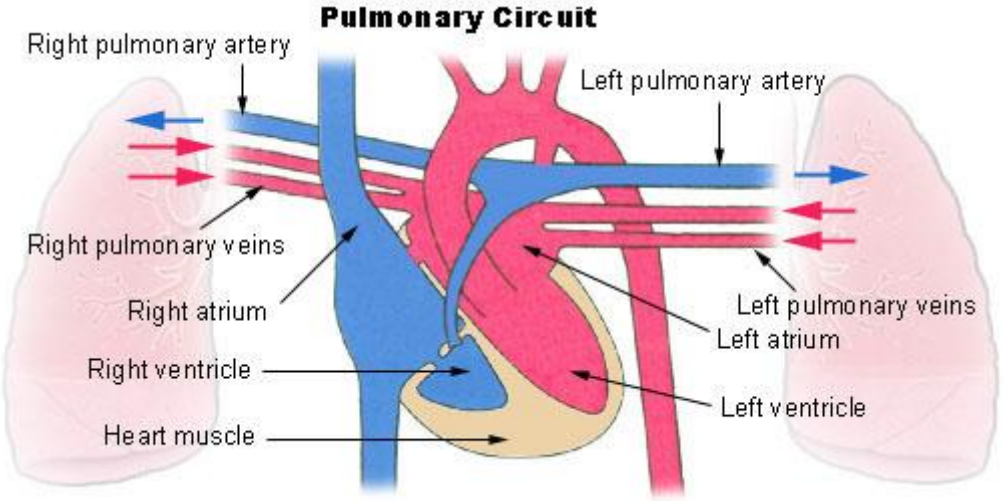

Systemic Circulation (Blood Circulation)

Systemic circulation is the part of the cardiovascular system which carries oxygenated blood away from the heart to the body, and returns deoxygenated blood back to the heart. The systemic circulation provides the functional blood supply to all body tissue. It carries oxygen and nutrients to the cells and picks up carbon dioxide and waste products.

Systemic circulation carries oxygenated blood from the left ventricle, through the arteries, to the capillaries in the tissues of the body. From the tissue capillaries, the deoxygenated blood returns through a system of veins to the right atrium of the heart.

Blood is circulate in closed system

***systemic**: heart ! rest of body ! heart:

Left ventricle! aorta! body! vena cava! rt atrium .

***pulmonary**: heart ! lungs ! heart:

right t ventricle! pulmonary arteries ! lungs! Pulmonary veins! left atrium.

Anatomy of Lymphatic System

Lymphatic System: an open system that returns excess materials in

the tissue spaces back to the blood. fluid = **lymph.**

Lymph: is isotonic solution , rich in fats , poor in protein carry by lymph vessels to lymph node . it contains high number of lymphocyte (WBC)

Lymphatic System consist of :

1. **Lymph vessels**: move lymph in one direction; lymph does not circulate.

2.Lymph glands: which found along the lymph vessels ,we can feel some lymph nodes eg: under the arm/in the neck

***** there are also lymph node that cannot feel eg: abdomen /pelvis

3.Spleen: It is a soft mass and it is the largest lymphatic organs .

It lies in the back of the left upper quadrant of the abdomen beneath the diaphragm .(left hypochondrium region) ,upper border reaches the 9th rib and lower border reaches the 11th rib . It thickness 1 inch ,width 3 inch , length 5 inch and weight 7 ounces (200gm).

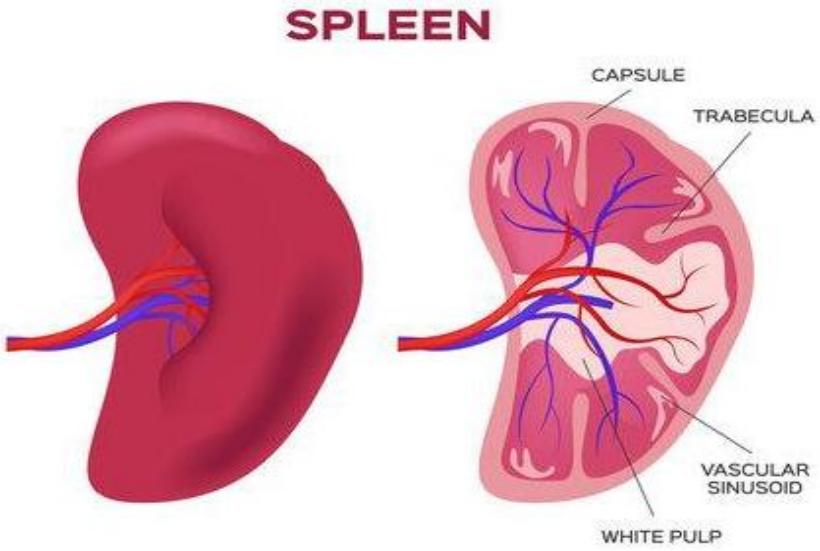

The spleen has some important functions:

1- fights invading germs in the blood (the spleen contains infection-fighting white blood cells).

2- controls the level of blood cells (white blood cells, red blood cells and platelets).

3- filters the blood and removes any old or damaged red blood cells.

4. the thymus : it a small gland under the breast , it is help to produce (T) cells in early life (immune function).

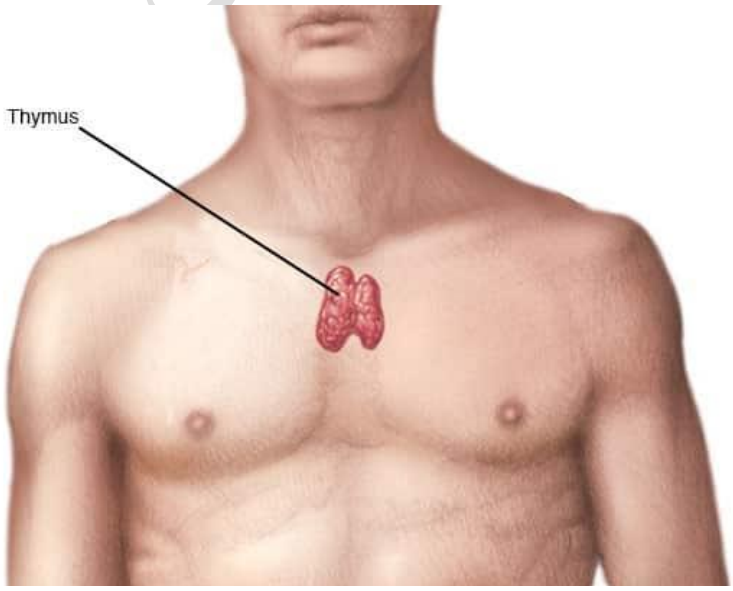

5.**the tonsils**: the two glands in the back of throat , they are help

to protect the entrance of digestive system and lungs from bacteria and viruses.