Cell Definition

"A cell is defined as the smallest, basic unit of life that is responsible for all of life's processes."

Cells are the structural, functional, and biological units of all living beings. A cell can replicate itself independently. Hence, they are known as the building blocks of life**.**

Each cell contains a fluid called the cytoplasm, which is enclosed by a membrane. Also present in the cytoplasm are several biomolecules like proteins, nucleic acids and lipids. Moreover, cellular structures called cell organelles are suspended in the cytoplasm

What is a Cell?

A cell is the structural and fundamental unit of life. The study of cells from its basic structure to the functions of every cell organelle is called Cell Biology. Robert Hooke was the first Biologist who discovered cells.

All organisms are made up of cells. They may be made up of a single cell (unicellular), or many cells (multicellular).

Discovery of Cells

Discovery of cells is one of the remarkable advancements in the field of science. It helps us know that all the organisms are made up of cells, and these cells help in carrying out various life processes. The structure and functions of cells helped us to understand life in a better way.

Characteristics of Cells

Following are the various essential characteristics of cells:

- Cells provide structure and support to the body of an organism.
- The cell interior is organised into different individual organelles surrounded by a separate membrane.
- The nucleus (major organelle) holds genetic information necessary for reproduction and cell growth.
- Every cell has one nucleus and membrane-bound organelles in the cytoplasm.
- Mitochondria, a double membrane-bound organelle is mainly responsible for the energy transactions vital for the survival of the cell.
- Lysosomes digest unwanted materials in the cell.

- Endoplasmic reticulum plays a significant role in the internal organisation of the cell by synthesising selective molecules and processing, directing and sorting them to their appropriate locations

Types of Cells

Cells are similar to factories with different labourers and departments that work towards a common objective. Various types of cells perform different functions. Based on cellular structure, there are two types of cells:

- Prokaryotes
- Eukaryotes

Prokaryotic Cells

1. Prokaryotic cells have no nucleus. Instead, some prokaryotes such as bacteria have a region within the cell where the genetic material is freely suspended. This region is called the nucleoid.
2. They all are single-celled microorganisms.

Eukaryotic Cells

Main article: Eukaryotic Cells

1. Eukaryotic cells are characterised by a true nucleus.
2. The size of the cells ranges between 10–100 μm in diameter.
3. This broad category involves plants, fungi, protozoans, and animals.
4. The plasma membrane is responsible for monitoring the transport of nutrients and electrolytes in and out of the cells. It is also responsible for cell to cell communication.
5. They reproduce sexually as well as asexually.
6. There are some contrasting features between plant and animal cells. For eg., the plant cell contains chloroplast, central vacuoles, and other plastids, whereas the animal cells do not.

Cell Structure

The cell structure comprises individual components with specific functions essential to carry out life's processes. These components include- cell wall, cell membrane, cytoplasm, nucleus, and cell organelles. Read on to explore more insights on cell structure and function.

Cell Membrane

- The cell membrane supports and protects the cell. It controls the movement of substances in and out of the cells. It separates the cell from the external environment. The cell membrane is present in all the cells.
- The cell membrane is the outer covering of a cell within which all other organelles, such as the cytoplasm and nucleus, are enclosed. It is also referred to as the plasma membrane.

Cell Wall

- The cell wall is the most prominent part of the plant's cell structure. It is made up of cellulose, hemicellulose and pectin.
- The cell wall is present exclusively in plant cells. It protects the plasma membrane and other cellular components. The cell wall is also the outermost layer of plant cells.

Cytoplasm

- The cytoplasm is a thick, clear, jelly-like substance present inside the cell membrane.
- Most of the chemical reactions within a cell take place in this cytoplasm

Nucleus

- The nucleus contains the hereditary material of the cell, the DNA.
- It sends signals to the cells to grow, mature, divide and die.
- The nucleus is surrounded by the nuclear envelope that separates the DNA from the rest of the cell.
- The nucleus protects the DNA and is an integral component of a plant's cell structure.

Cell Organelles

Cells are composed of various cell organelles that perform certain specific functions to carry out life's processes. The different cell organelles, along with its principal functions, are as follows:

Cell Organelle and its Functions
Nucleolus
The nucleolus is the site of ribosome synthesis. Also, it is involved in controlling cellular activities and cellular reproduction
Nuclear membrane
The nuclear membrane protects the nucleus by forming a boundary between the nucleus and other cell organelles.
Chromosomes
Chromosomes play a crucial role in determining the sex of an individual. Each human cells contain 23 pairs of chromosomes
Endoplasmic reticulum
The endoplasmic reticulum is involved in the transportation of substances throughout the cell. It plays a primary role in the metabolism of carbohydrates, يعني of lipids, steroids and proteins.
Golgi Bodies

Golgi bodies are called the cell's post office as it is involved in the transportation of materials within the cell
Ribosome
Ribosomes are the protein synthesisers of the cell
Mitochondria
The mitochondrion is called "the powerhouse of the cell." It is called so because it produces ATP – the cell's energy currency
Lysosomes
Lysosomes protect the cell by engulfing the foreign bodies entering the cell and helps in cell renewal. Therefore, it is known as the cell's suicide bags
Chloroplast
Chloroplasts are the primary organelles for photosynthesis. It contains the pigment chlorophyll
Vacuoles
Vacuoles stores food, water, and other waste materials i

Questions

State the types of cells.

What are the functions of the cell?

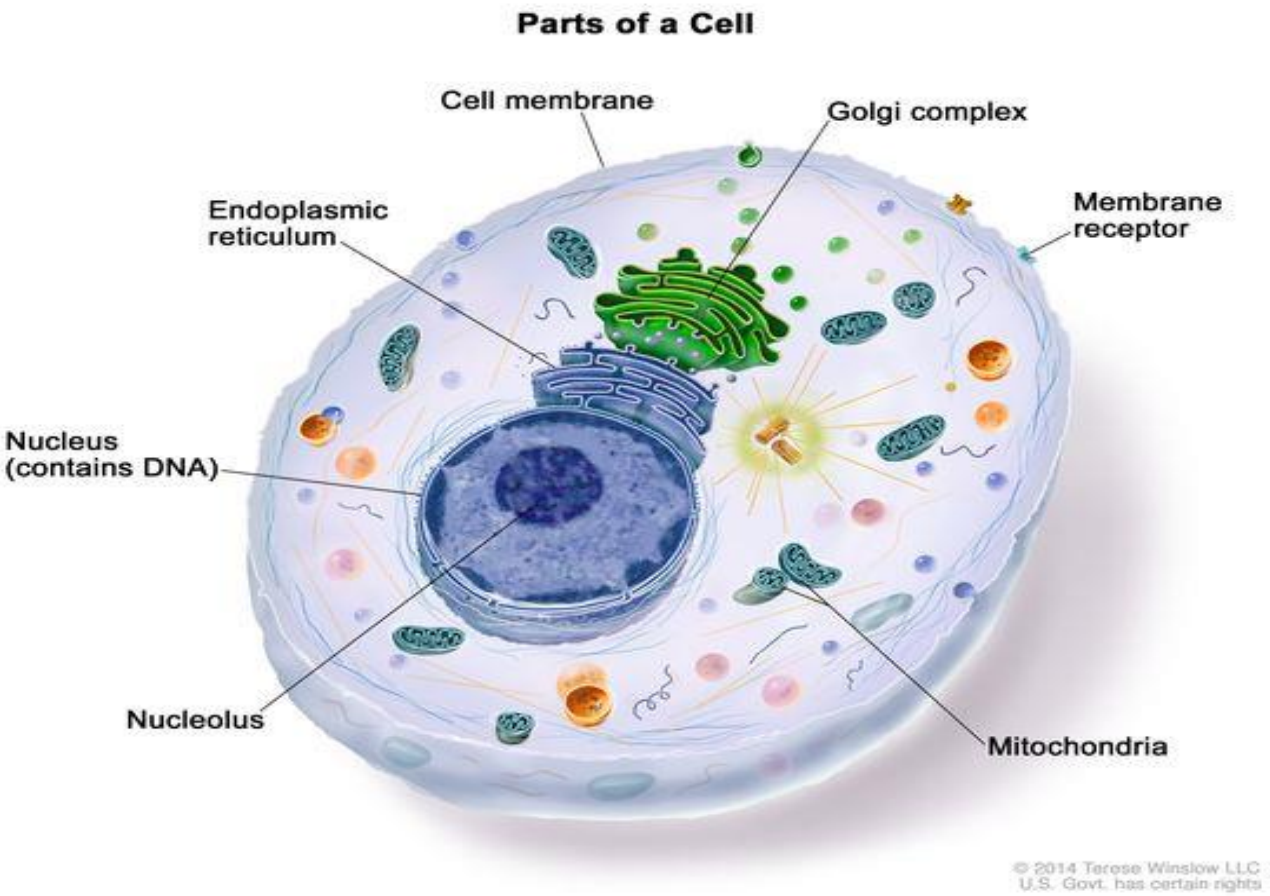

The Tissues

A tissue is an ensemble of similar cells from the same origin that together carry out a specific function.

Organs are then formed by the functional grouping together of multiple tissues.

Cells: are the building blocks of life – all living organisms are made up of them. the shapes of cells can vary widely. Animal cells in particular come in all kinds of shapes and sizes. Plant cell shapes tend to be quite similar to each other because of their rigid cell wall,Cells have different shapes because they do different things. Each cell type has its own role to play in helping our bodies to work properly, and their shapes help them carry out these roles effectively.

The study of tissue is known as Histology

Histology : is the study of the microscopic anatomy of cells and tissues of plants and animals, its commonly performed by examining cells and tissues under a light microscope or electron microscope .

Histological studies may be conducted using tissue culture. Histology is an essential tool of biology medicine .

Histopathology : the microscopic study of diseased tissue , accurate diagnosis of cancer and other disease usually requires histopathological examination of samples .

The classical appearance of tissues can be examined in health and disease enabling considerable refinement of medical diagnosis and prognosis .

1

Types of tissues

there are four basic types of animal tissues: Epithelial tissue. , connective tissue ,muscle tissue & nervous tissue, and All tissue types are subtypes of these four basic tissue

Epithelium

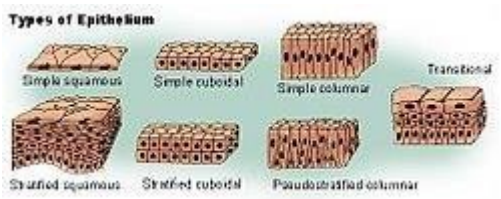

Types of epithlium

Epithelium: is one of the four basic types of animal tissue, along with connective tissue, muscle tissue and nervous tissue.

Epithelial tissues line the cavities and surfaces of blood vessels and organs throughout the body.

There are three principal shapes of epithelial cell: squamous ,columnar, and cuboidal. These can be arranged in a single layer of cells as simple epithelium,

All glands are made up of epithelial cells. Functions of epithelial cells include secretion, selective absorption, protection, transcellular transport, and sensing.

Epithelial tissue, or epithelium, has the following general characteristics:

- Epithelium consists of closely packed, flattened cells that make up the inside or outside lining of body areas. There is little intercellular material.
- The tissue is **avascular,** meaning without blood vessels. Nutrient and waste exchange occurs through neighboring connective tissues by diffusion.

- The upper surface of epithelium is free, or exposed to the outside of the body or to an internal body cavity. The basal surface rests on connective tissue. A thin, extracellular layer called the *basement membrane* forms between the epithelial and connective tissue.

There are two kinds of epithelial tissues:

- Covering and lining epithelium covers the outside surfaces of the body and lines internal organs.
- Glandular epithelium secretes hormones or other products.

Epithelium that covers or lines

Classification

In general, epithelial tissues are classified by the number of their layers and by the shape and function of the cells.

The three principal shapes associated with epithelial cells are—squamous, cuboidal and columnar.

- **Squamous epithelium** has cells that are wider than their height (flat and scalelike).
- **Cuboidal epithelium** has cells whose height and width are approximately the same (cube shaped).

- **Columnar epithelium** has cells taller than they are wide (column-shaped).

By layer, epithelium is classed as either simple epithelium, only one cell thick (unilayered) or stratified epithelium as stratified squamous epithelium, stratified cuboidal epithelium, and stratified columnar epithelium that are two or more cells thick (multi-layered), and both types of layering can be made up of any of the cell shapes.

Simple epithelium

Simple epithelium is a single layer of cells with every cell in direct contact with the basement membrane that separates it from the underlying connective tissue. In general, it is found where absorption and filtration occur. The thinness of the epithelial barrier facilitates these processes.

In general, simple epithelial tissues are classified by the shape of their cells. The four major classes of simple epithelium are: .

(1) simple squamous; which is found lining areas where passive diffusion of gases occur. e.g. skin, walls of capillaries, linings of the pericardial, pleural, and peritoneal cavities, as well as the linings of the alveoli of the lungs.

(2) simple cuboidal: these cells may have secretory, absorptive, or excretory functions. examples include small collecting ducts of kidney, pancreas, and salivary gland.

(3) simple columnar; cells can be secretory, absorptive, or excretory; Simple columnar epithelium can be ciliated or non-ciliated; ciliated columnar is found in the female reproductive tract and uterus. Non-ciliated epithelium can also possess microvilli.

4) pseudostratified columnar epithelium; when taller simple columnar epithelial cells are viewed in cross section showing several nuclei appearing at different heights, they can be confused with stratified epithelia. This kind of epithelium is therefore described as pseudostratified columnar epithelium .

Stratified epithelium :

Stratified epithelium differs from simple epithelium in that it is multilayered.

Stratified epithelia (of columnar, cuboidal or squamous type) can have the following specializations:

Keratinized : In this particular case, the most apical layers (exterior) of cells are dead and lose their nucleus and cytoplasm, instead contain a tough, resistant protein called keratin. This specialization makes the epithelium water proof, so is found in the mammalian skin. The lining of the esophagus is an example of a non-keratinized or "moist" stratified epithelium

In this case, the most apical layers of cells are filled with keratin, but they still retain their nuclei.

Transitional epithelia: its found in tissues that stretch and it can appear to be stratified cuboidal when the tissue is not stretched or stratified squamous when the organ is distended and the tissue stretches. It is sometimes called urothelium since it is almost exclusively found in the bladder, ureters and urethra-.

Structure:

Cells of epithelial tissue are tightly packed and form a continuous sheet. They have almost no intercellular spaces. All epithelia is usually separated from underlying tissues by an extracellular fibrous basement membrane.

Location

See also: Table of epithelia of human organs

Epithelium lines both the outside (skin) and the inside cavities and lumina of bodies. The outermost layer of human skin is composed of dead stratified squamous, keratinized epithelial cells.

Tissues that line the inside of the mouth, the esophagus and part of the rectum are composed of nonkeratinized stratified squamous epithelium. Other surfaces that separate body cavities from the outside environment are lined by simple squamous, columnar, or pseudo stratified epithelial cells. Other epithelial cells line the insides of the lungs, the gastrointestinal tract, the reproductive and urinary tracts, and make up

the exocrine and endocrine glands. The outer surface of the cornea is covered with fast-growing, easily regenerated epithelial cells. A specialised form of epithelium – endothelium forms the inner lining of blood vessels and the heart, and is known as vascular endothelium, and lining lymphatic vessels as lymphatic endothelium. Another type, mesothelium, forms the walls of the pericardium, pleurae, and peritoneum.

Basement membrane

Epithelial tissue rests on a basement membrane, which acts as a scaffolding on which epithelium can grow and regenerate after injuries Epithelial tissue has a nerve supply, but no blood supply and must be nourished by substances diffusing from the blood vessels in the underlying tissue. The basement membrane acts as a selectively permeable membrane that determines which substances will be able to enter the epithelium.

Development

Epithelial tissues are derived from all of the embryological germ layers

- from ectoderm (e.g., the epidermis);
- from endoderm (e.g., the lining of the gastrointestinal tract); ▫ from mesoderm (e.g., the inner linings of body cavities).

Glandular tissue

Glandular tissue is the type of epithelium that forms the glands from the in folding of epithelium and subsequent growth in the underlying connective tissue. There are two major classifications of glands: endocrine glands and exocrine glands:

- Endocrine glands secrete their product into the extracellular space where it is rapidly taken up by the blood vascular system.
- Exocrine glands secrete their products into a duct that then delivers the product to the lumen of an organ or onto the free surface of the epithelium.

Figure 1. Types of epithelial tissues.

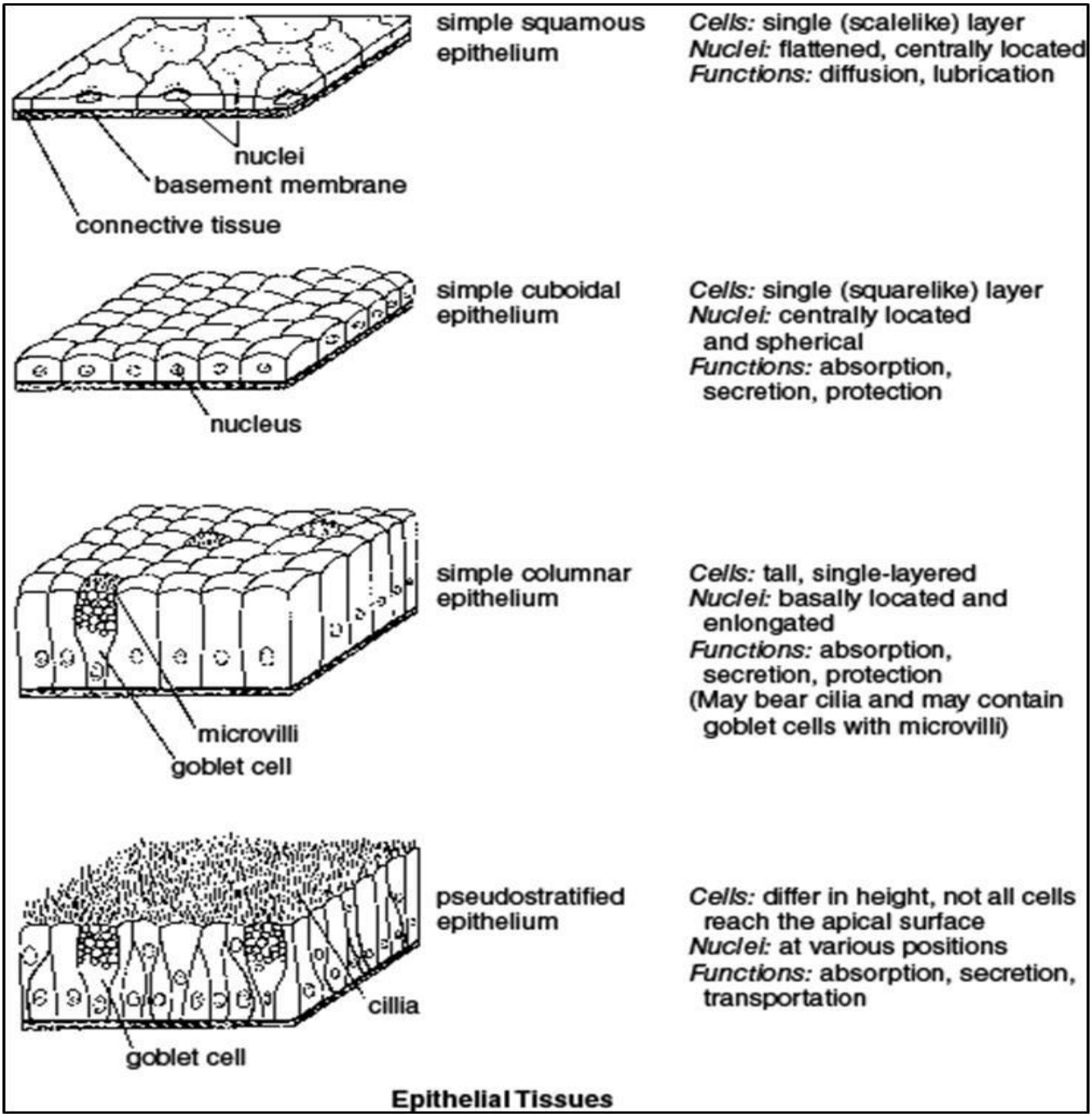
simple squamous epithelium
Cells: single (scalelike) layer
Nuclei: flattened, centrally located
Functions: diffusion, lubrication
nuclei
basement membrane
connective tissue
simple cuboidal epithelium
Cells: single (squarelike) layer
Nuclei: centrally located and spherical
Functions: absorption, secretion, protection
nucleus
simple columnar epithelium
Cells: tall, single-layered
Nuclei: basally located and enlongated
Functions: absorption, secretion, protection
(May bear cilia and may contain goblet cells with microvilli)
microvilli
goblet cell
pseudostratified epithelium
Cells: differ in height, not all cells reach the apical surface
Nuclei: at various positions
Functions: absorption, secretion, transportation
cillia
goblet cell
Epithelial Tissues

Figure 2. Types of Stratified epithelial tissues

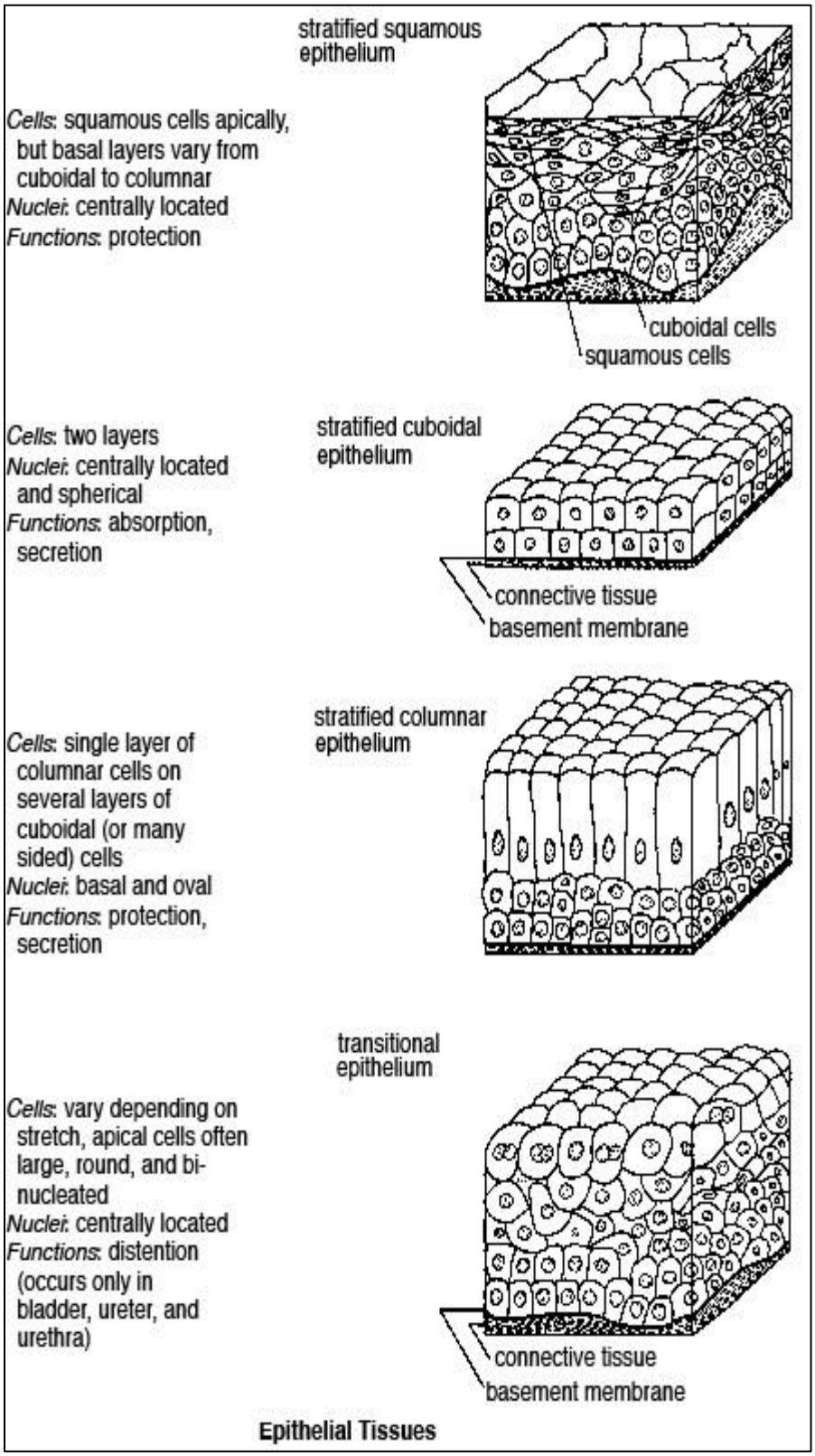

Epithelial Tissues

Cells	Location	Function
Simple squamous epithelium 	Air sacs of lungs and the lining of the heart, blood vessels, and lymphatic vessels	Allows materials to pass through by diffusion and filtration, and secretes lubricating substance
Simple cuboidal epithelium 	In ducts and secretory portions of small glands and in kidney tubules	Secretes and absorbs
Simple columnar epithelium 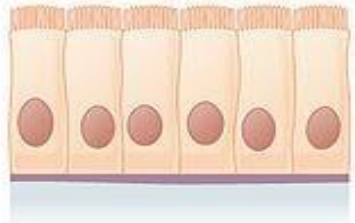	Ciliated tissues are in bronchi, uterine tubes, and uterus; smooth (nonciliated tissues) are in the digestive tract, bladder	Absorbs; it also secretes mucous and enzymes
Pseudostratified columnar epithelium 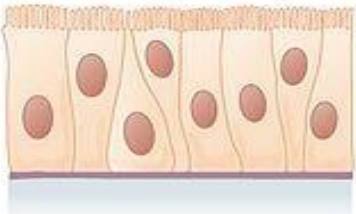	Ciliated tissue lines the trachea and much of the upper respiratory tract	Secretes mucus; ciliated tissue moves mucus
Stratified squamous epithelium 	Lines the esophagus, mouth, and vagina	Protects against abrasion
Stratified cuboidal epithelium 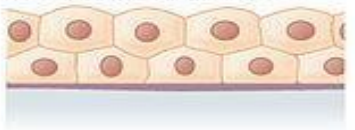	Sweat glands, salivary glands, and the mammary glands	Protective tissue
Stratified columnar epithelium 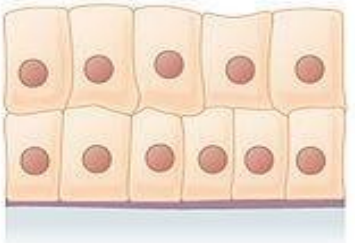	The male urethra and the ducts of some glands	Secretes and protects
Transitional epithelium 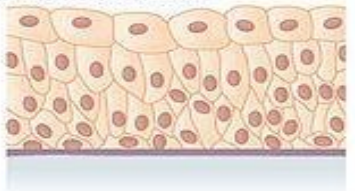	Lines the bladder, uretha, and the ureters	Allows the urinary organs to expand and stretch

Connective tissue

Connective tissue:- group of tissues in the body that maintain the form of the body and its organs and provide cohesion and internal support. The connective tissues include several types of fibrous tissue that vary only in their density and cellularity, as well as the more specialized and recognizable variants—bone, ligaments, tendons, cartilage, and adipose (fat) tissue.

* In the abdominal cavity, most organs are suspended from the abdominal wall by a membranous band known as the mesentery, which is supported by connective tissue; others are embedded in adipose tissue, a form of connective tissue in which the cells are specialized for the synthesis and storage of energy-rich reserves of fat, or lipid.

Components Of Connective Tissue

All forms of connective tissue are composed of

(1) extracellular fibres,

(2) an amorphous matrix called ground substance, and

(3) stationary and migrating cells.

The proportions of these components vary from one part of the body to another depending on the local structural requirements. In some areas, the connective tissue is loosely organized and highly cellular; in others, its fibrous components predominate; and in still others, the ground substance may be its most conspicuous feature.

Ground substance:

Ground substance is a colorless, transparent, gel-like material in which the cells and fibers
of connective tissue are embedded. It is a complex mixture of glycosaminoglycans**,**
proteoglycans**,** and glycoproteins. Ground substance is a lubricant, helps prevent invasion
of tissues by foreign agents, and resists forces of compression.

Cells in connective tissue

Types of cells found in connective tissue.

1- Fibroblasts. These are the least specialised of all the cells. They are mainly responsible for secreting the non-rigid extracellular matrix including the fibres: collagen, elastin or fibronectin.

2- Adipocytes. These are fat storing cells, which are thought to derive from fibroblastic like cells.
3- Macrophages, Mast cells and Plasma cells. These are all types of Immune cell.

Connective tissue fibers:

- **Collagenous fibers:** are made of collagen and consist of bundles of fibrils that are coils of collagen molecules.
- **Elastic Fibers**: are made of the protein elastin and are stretchable.
- **Reticular Fibers:** join connective tissues to other tissues.

CLASSIFICATION OF CONNECTIVE TISSUE (BASED ON STRUCTURE AND FUNCTION)

Connective tissue can broadly be classified into following five categories:

A- CONNECTIVE TISSUE PROPER

1- Dense Connective Tissue: contains more fibers but fewer cells than loose connective tissue. It is classified by the orientation of its fiber bundles into two types:

a- Dense irregular connective tissue: (most common), which contains fiber bundles that have no definite orientation. This tissue is characteristic of the dermis of the skin and capsules of many organs.

b- Dense regular connective tissue: contains bundles of white collagenous fibers. In this tissue, the bundles are parallel as in tendons (which connect muscles to bones) and ligaments (which connect bones to other bones at joints). Some dense connective tissue has elastic fibers, which allow the tissue to stretch and recoil. Examples are the vocal cords and the walls of large arteries.

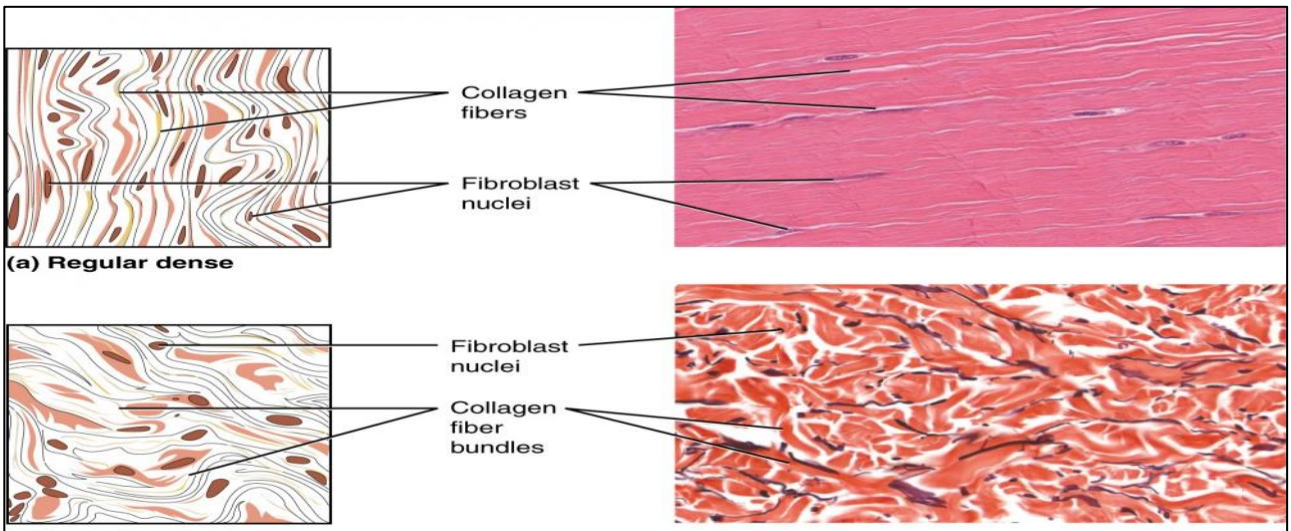

2- Loose Connective Tissue (areolar connective tissue)

It is a vascular, delicate, flexible connective tissue where the fibers are loosely

arranged. It serves as a packing material by filling spaces between various tissue components of an organ and giving it a shape, e.g. subperitoneal tissue, en

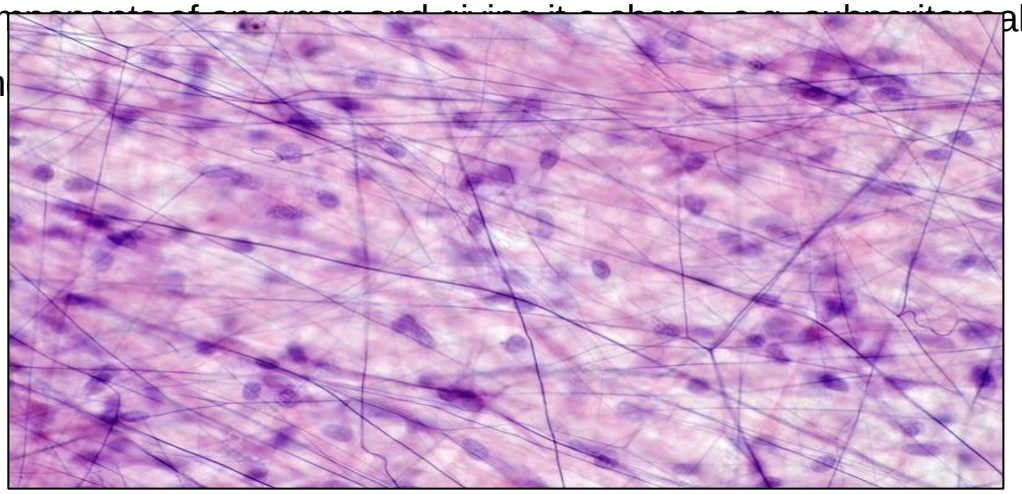

B-SPECIALIZED CONNECTIVE TISSUES

Adipose Tissue: contains very little matrix, and the adipocytes (fat cells) are large and

closely packed together. These cells present under skin, around organs such as the heart and kidneys, in the breast, and in cavities within bones. Adipose cells are filled with lipids and function to store energy. Adipose tissue also pads and protects parts of the body and acts as a thermal insulator.

Cartilage

Cartilage is a form of fibrous connective tissue that is composed of closely packed collagenous fibers in a rubbery gelatinous substance called chondrin ,The skeletons of sharks and human embryos are composed of cartilage. Cartilage also provides flexible support for certain structures in adult humans including the nose, trachea, and ears.

Bone

Bone is a type of mineralized connective tissue that contains collagen and calcium phosphate, a mineral crystal. Calcium phosphate gives bone its firmness.

Blood

Interestingly enough, blood is considered to be a type of connective tissue. Even though it has a different function in comparison to other connective tissues it does have an extracellular matrix. The matrix consists of the plasma, while red blood cells,white blood cells, and platelets are suspended in the plasma.

Lymph

Lymph is another type of fluid connective tissue. This clear fluid originates from blood plasma that exits blood vessels at capillary beds. A component

of the lymphatic system, lymph contains immune system cells that protect the body against pathogens.

Al-Furat Al-Awsat Technical University
The First Class
Technical Institute/Kufa
The First lecture
Department of Medical Laboratory Techniques
Histology

What is blood?

Blood is considered a connective tissue because it has a matrix. It is thick because it is made up of a variety of cells, each having a different job. In fact, blood is about 80% water and 20% solid. Blood is made mostly of plasma, but 3 main types of blood cells circulate with the plasma:

1- Red blood cells: carry oxygen. Of the 3 types of blood cells, red blood cells are the most plentiful. In fact, a healthy adult has about 35 trillion of them. The body creates these cells at a rate of about 2.4 million a second, and they each have a life span of about 120 days. Red blood cells are also called erythrocytes. 2- White blood cells: ward off infection. These cells, which come in many shapes and sizes, are vital to the immune system. When the body is fighting off infection, it makes them in ever-increasing numbers. Still, compared to the number of red blood cells in the body, the number of white blood cells is low. Most healthy adults have about 700 times as many red blood cells as white ones. White blood cells are also called leukocytes.

2- Platelets help the blood to clot: Clotting stops the blood from flowing out of the body when a vein or artery is broken. Platelets are also called thrombocytes.

Blood also contains hormones, fats, carbohydrates, proteins, and gases.

Al-Furat Al-Awsat Technical University
Technical Institute/Kufa
Department of Medical Laboratory Techniques

The First Class

The First lecture

Histology

What does blood do?

1-Blood carries oxygen from the lungs and nutrients from the digestive tract to the body's cells. It also carries away carbon dioxide and all of the waste products that the body does not need. 2-Helps keep your body at the right temperature

3-Carries hormones to the body's cells

4-Sends antibodies to fight infection

5-Contains clotting factors to help the blood to clot and the body's tissues to heal

White blood cells circulate around the blood and help the immune system fight off infections.Stem cells in the bone marrow are responsible for producing white blood cells. The bone marrow then stores an estimated 80–90% of white blood cells.

When an infection or inflammatory condition occurs, the body releases white blood cells to help fight the infection.

In this article, learn more about white blood cells, including the types and their functions.

Types and function

Health professionals have identified three main categories of white blood cell: granulocytes, lymphocytes, and monocytes. The sections below discuss these in more detail. Granulocytes:-

Granulocytes are white blood cells that have small granules containing proteins. There are three types of granulocyte cells:

a-Basophils: These represent less than 1% of white blood cells in the body and are typically present in increased numbers after an allergic reaction.

b-Eosinophils: These are responsible for responding to infections that parasites cause. They also play a role in the general immune response, as well as the inflammatory response, in the body.

c-Neutrophils: These represent the majority of white blood cells in the body. They act as scavengers, helping surround and destroy bacteria and fungi that may be present in the body.

Lymphocytes:-

These white blood cells include the following:

B cells: Also known as B-lymphocytes, these cells produce antibodies to help the immune system mount a response to infection.

T cells: Also known as T-lymphocytes, these white blood cells help recognize and remove infection-causing cells.

Natural killer cells: These cells are responsible for attacking and killing viral cells, as well as cancer cells.

Monocytes:

A type of immune cell that is made in the bone marrow and travels through the blood to tissues in the body where it becomes a macrophage or a dendritic cell. Macrophages surround and kill microorganisms, ingest foreign material, remove dead cells, and boost immune responses. During inflammation, dendritic cells boost immune responses by showing antigens on their surface to other cells of the immune system. A monocyte is a type of white blood cell and a type of phagocyte.

Al-Furat Al-Awsat Technical University
The First Class
Technical Institute/Kufa
The First lecture
Department of Medical Laboratory Techniques
Histology

The Bone

Bone, rigid body tissue consisting of cells embedded in an abundant hard intercellular material. The two principal components of this material, collagen and calcium phosphate, distinguish bone from such other hard tissues as chitin, enamel, and shell. Bone tissue makes up the individual bones of the human skeletal system and the skeletons of other vertebrates.

Spongy Bone

Spongy bone is also called cancellous or trabecular bone. It is found in the long bones and it is surrounded by compact bone. The term spongy comes from the fact that it is a highly vascularized and porous tissue. Trabeculae are spaces created in the tissue by thin areas of osteoblast cells. As a result, trabecular bone has about 10 times the surface area of compact bone. It also makes up about 20% of a human skeleton. Spongy bone is home to the bone marrow and hematopoietic stem cells that differentiate into red blood cells, white blood cells and platelets.

Compact Bone

Compact bone, also called cortical bone, surrounds spongy bone and makes up the other 80% of the bone in a human skeleton. It is smooth, hard and heavy compared to spongy bone and

it is also white in appearance, in contrast to spongy bone which has a pink color. Compact bone is made up of units called lamellae which are sheets of collagen aligned in a parallel pattern that gives the bone strength. Compact bone is formed from a number of *osteons*, which are circular units of bone material and blood vessels. These units allow compact bone to remain hard and compact while still receiving nutrients from the body and disposing of waste through the same channels(Haversian canals). Each osteon is also composed of a number of different cells responsible for the maintenance of the bones, including *osteocytes* and *osteoblasts*.

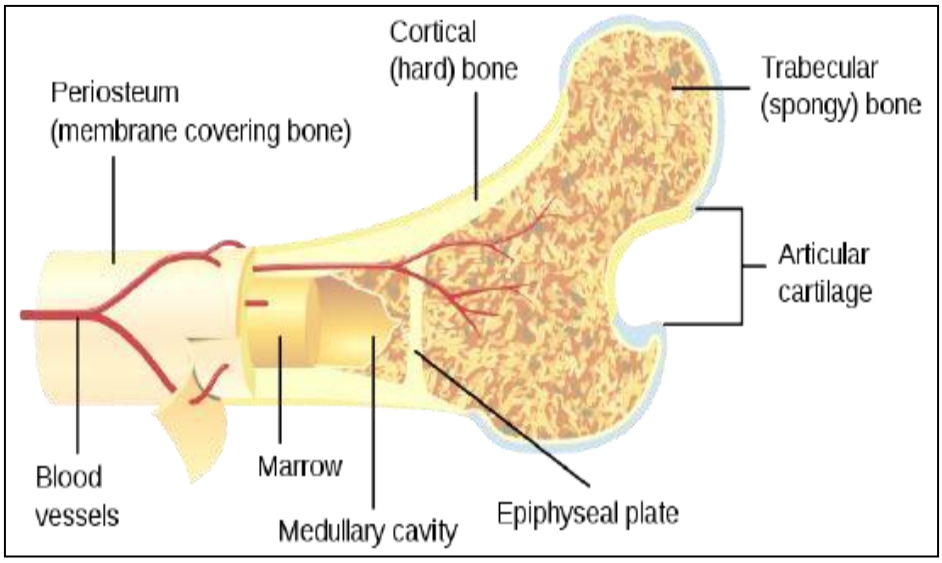

(1)Cross-section of a bone showing trabecular and cortical bone.

Bone cells

Bone tissue contains many different cell types that constantly resize and reshape bones throughout growth and adulthood. Bone tissue cells include osteoprogenitor cells, osteoblasts, osteoclasts, and osteocytes. The osteoprogenitor cells are cells that have not matured yet. Once they are stimulated, some will become osteoblasts which are involved in the creation and mineralization of bone tissue(the bone builders), and others will become osteoclasts, the cells that break bone down. Osteocytes are the most abundant cells in bone tissue. Osteocytes are star-shaped cells that are connected throughout the bone and exchange nutrients from bones to the blood and lymph.

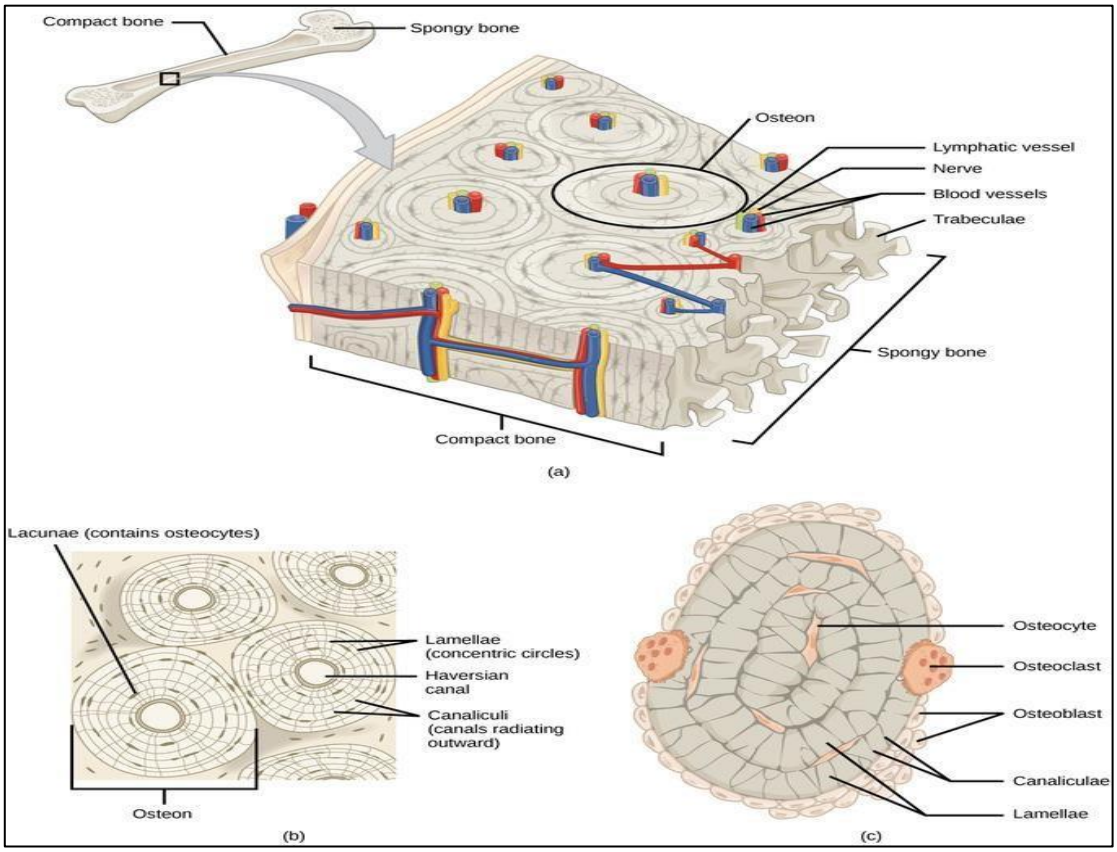

Bone structure: (a) Compact bone is a dense matrix on the outer surface of bone. Spongy bone, inside the compact bone, is porous with web-like trabeculae. (b) Compact bone is organized into rings called osteons. Blood vessels, nerves, and lymphatic vessels are found in the central Haversian canal. Rings of lamellae surround the Haversian canal. Between the lamellae are cavities called lacunae. Canaliculi are microchannels connecting the lacunae together. (c) Osteoblasts surround the exterior of the bone. Osteoclasts bore tunnels into the bone and osteocytes are found in the lacunae.

Cartilage

Cartilage is an important structural component of the body. It is a firm tissue but is softer and much more flexible than bone .Cartilage is a connective tissue found in many areas of the body including:

- Joints between bones e.g. the elbows, knees and ankles
- Ends of the ribs
- Between the vertebrae in the spine
- Ears and nose
- Bronchial tubes or airways

Cartilage is made up of specialized cells called chondrocytes. These chondrocytes produce large amounts of extracellular matrix composed of collagen fibres, proteoglycan, and elastin fibers. There are no blood vessels in cartilage to supply the chondrocytes with nutrients.

Instead, nutrients diffuse through a dense connective tissue surrounding the cartilage (called the perichondrium) and into the core of the cartilage. Due to the lack of blood vessels, cartilage grows and repairs more slowly than other tissues.

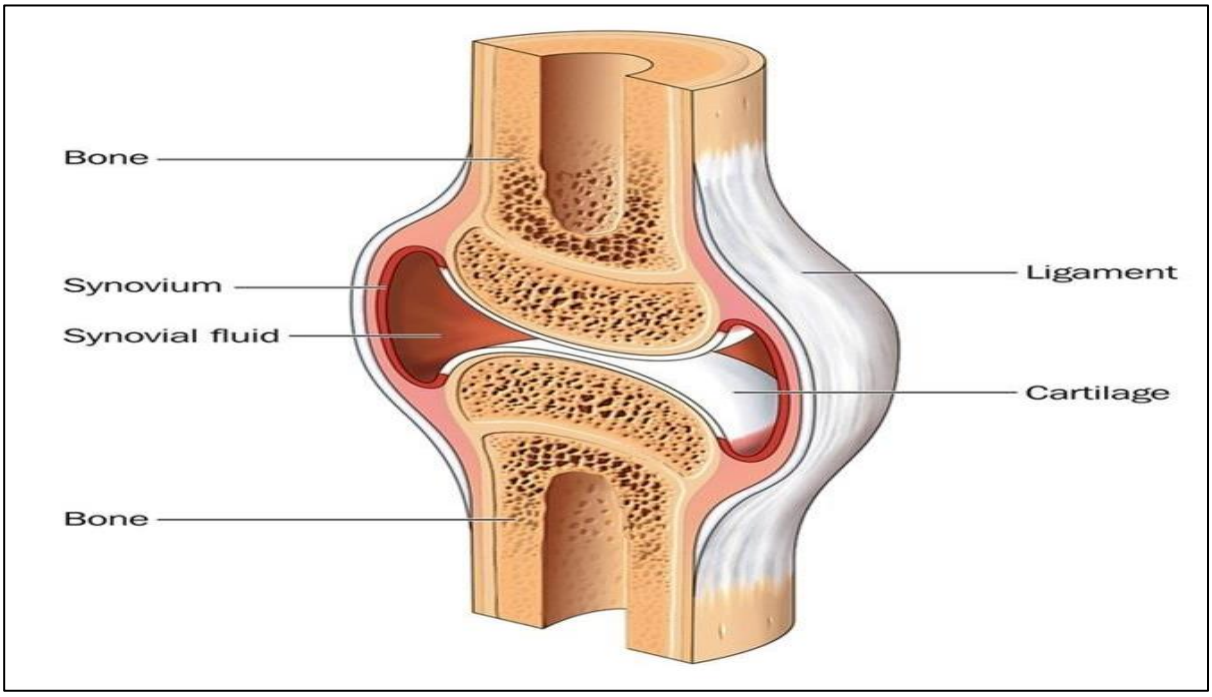

Cross section through a typical synovial joint, showing the bone, synovial membrane, synovial fluid, cartilage and ligament - Image Credit: Blamb / Shutterstock

Cartilage type

Cartilage is categorized into three types which include:

- **Hyaline cartilage**

This is a low-friction, wear-resistant tissue present within joints that is designed to bear and distribute weight. It is a strong, rubbery, flexible tissue but has a poor regenerative capacity.

- **Elastic cartilage**

Elastic cartilage is more flexible that hyaline cartilage and is present in the ear, larynx and epiglottis.

- **Fibrocartilage**

Fibrocartilage is a tough and inflexible form of cartilage found in the knee and between vertebrae.

Articular cartilage

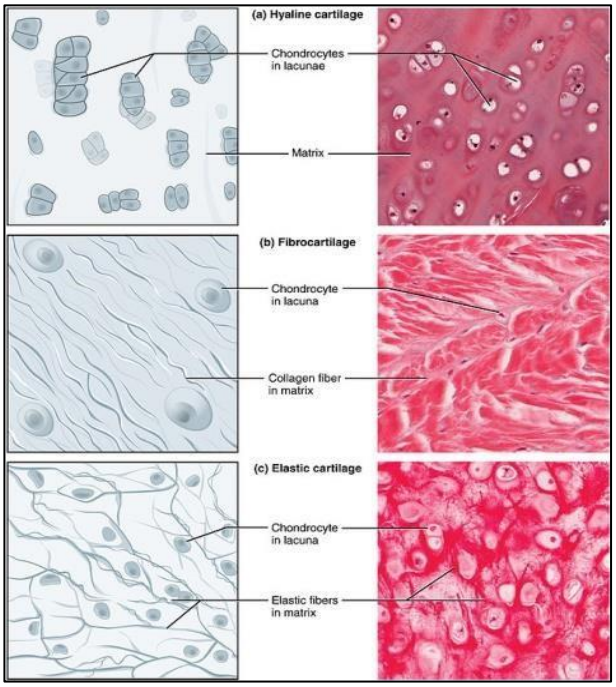

Type of cartilage

Al-Furat Al-Awsat Technical University
Technical Institute/Kufa
Department of Medical Laboratory Techniques

The First Class
The First lecture
Histology

Muscle Tissue

Muscle tissue is composed of cells that have the special ability to shorten or contract in order to produce movement of the body parts. The tissue is highly cellular and is well supplied with blood vessels. The cells are long and slender so they are sometimes called muscle fibers, and these are usually arranged in bundles or layers that are surrounded by connective tissue. Actin and myosin are contractile proteins in muscle tissue.

Muscle Cell

Muscle fiber (Myofibra)Muscle cells, commonly known as myocytes, are the cells that make up muscle tissue. There are 3 types of muscle cells in the human body; cardiac, skeletal, and smooth. Cardiac and skeletal myocytes are sometimes referred to as muscle fibers due to their long and fibrous shape. Cardiac muscle cells, or cardiomyocytes, are the muscle fibers comprise

the myocardium, the middle muscular layer, of the heart. A muscle fibre (muscle cell) contains bundle of myofibril

• myofibrils are made of myofilaments

Myofilament

1-Thick myofilaments- myosin protein 2-Thin myofilaments- actin protein

Cross striations are the result of overlapping of myosin protein& actin protein

Muscle Types:-

Muscle tissue can be categorized into skeletal muscle tissue, smooth muscle tissue, and cardiac muscle tissue.

1-Skeletal muscle

Skeletal muscle, also called voluntary muscle, in vertebrates, most common of the three types of muscle in the body. Skeletal muscles are multi-nucleated meaning that they have more than one nucleus,they are attached to bones by tendons, and they produce all the movements of body parts in relation to each other. Unlike smooth muscle and cardiac muscle, skeletal muscle is under voluntary control. Similar to cardiac muscle, however, skeletal muscle is striated; its long, thin, multinucleated fibres are crossed with a regular pattern of fine red and white lines, giving the muscle a distinctive appearance. Skeletal muscle fibres are bound together by connective tissue and communicate with nerves and blood vessels. For more information on the structure and function of skeletal muscle.

Structure:

Skeletal muscle tissue is made up of a collection of muscle fibers wrapped in connective tissue sheaths. There are three types of connective tissue sheaths named for their location. Endomysium surrounds individual muscle fibers. It is made up of a delicate layer of reticular fibers and permits only small-diameter nerve fibers and capillaries, thus acting as a site of metabolic exchange.

Perimysium is a slightly thicker layer of connective tissue consisting mainly of type I and III collagen and surrounds a group of fibers. This fiber group is referred to as a fascicle or bundle. Fascicles are the functional units of skeletal muscle tissue.

The perimysium contains slightly larger blood vessels and nerve fibers than those traveling through endomysium.

Epimysium surrounds the entire collection of fascicles making up an individual muscle. This dense connective tissue made up of mainly type I collagen contains the neurovascular supply to the muscle.

2-Smooth Muscle

Smooth muscle, found in the walls of the hollow internal organs such as blood vessels, the gastrointestinal tract, bladder, and uterus, is under control of the autonomic nervous system.

Smooth muscle cannot be controlled consciously and thus acts involuntarily. The nonstriated (smooth) muscle cell is spindle-shaped and has one central nucleus. Smooth muscle contracts slowly and rhythmically.

3-Cardiac Muscle

Cardiac muscle, found in the walls of the heart, is also under control of the autonomic nervous system. The cardiac muscle cell has one central nucleus, like smooth muscle, but it also is striated, like skeletal muscle. The cardiac muscle cell is rectangular in shape. The contraction of cardiac muscle is involuntary, strong, and rhythmical.

Al-Furat Al-Awsat Technical University
Technical Institute/Kufa
Department of Medical Laboratory Techniques

The First Class
The First lecture
Histology

Nervous Tissue Definition

Nervous tissue is the term for groups of organized cells in the nervous system, which is the organ system that controls the body's movements, sends and carries signals to and from the different parts of the body, and has a role in controlling bodily functions such as digestion. Nervous tissue is grouped into two main categories: neurons and neuroglia. Neurons, or nerves, transmit electrical impulses, while neuroglia do not; neuroglia have many other functions including

Supporting and protecting neurons.

Al-Furat Al-Awsat Technical University
The First Class
Technical Institute/Kufa
The First lecture
Department of Medical Laboratory Techniques
Histology

Structure Of Nervous Tissue

It is made of nerve cells or neurons, all of which consists of an axon. Axons are long stem- like projections emerging out of the cell, responsible for communicating with other cells

Called the Target cells, thereby passing impulses

The axon is surrounded by a whitish, fatty layer called the myelin sheath

The main part is the cell body which contains the nucleus, cytoplasm, Nissl bodies and cell organelles. Extensions of the cell membrane are referred to as processes.

Dendrite: is a highly branched processes, responsible for receiving information from other neurons and synapses (specialized point of contact). Information of other neurons is

Provided by dendrites to connect with its cell body.

Information in a neuron is unidirectional as it passes through neurons from dendrites, across the cell body down the axon.

Al-Furat Al-Awsat Technical University
The First Class
Technical Institute/Kufa
The First lecture
Department of Medical Laboratory Techniques
Histology

Neuroglia:

There are six types of neuroglia—four in the central nervous system and two in the PNS. These glial cells are involved in many specialized functions apart from support of the neurons. Neuroglia in the CNS include astrocytes, microglial cells, ependymal cells and oligodendrocytes. In the PNS, satellite cells and Schwann cells are the two kinds of neuroglia.

Microglial cells: Microglia are macrophage cells that make up the primary immune system for the CNS , They are the smallest neuroglial cell

Astrocytes: Star-shaped macroglial cells with many processes found in the CNS. They are the most abundant cell type in the brain, and are intrinsic to a healthy CNS

Oligodendrocytes: CNS cells with very few processes. They form myelin sheaths on the axons of a neuron .

Ependymal cell:type of neuronal support cell (neuroglia) that forms the epithelial lining of the ventricles (cavities) in the brain and the central canal of the spinal cord.

Satellite glial cell: Line the ganglia (groups of nerve body cells bundled or connected together in the PNS) Schwann Cells:

Schwann cells surround all nerve fibers in the peripheral nervous system and form myelin sheaths around the nerve fibers. They are found in the PNS. Their function is similar to

Oligodendrocytes.

Synapse: also called neuronal junction, the site of transmission of electric nerve impulses between two nerve cells (neurons) or between a neuron and a gland or muscle cell (effector).

Al-Furat Al-Awsat Technical University
Technical Institute/Kufa
Department of Medical Laboratory Techniques

The First Class
The First lecture
Histology

Nervous Tissue Location

The nerve tissue or the nervous tissue is the chief tissue component of the two major parts of the nervous tissue – Central nervous system(CNS) formed by the spinal cord and the brain and the branching peripheral nerves of the peripheral nervous system (PNS) that control and

Regulate the functions of the body and their activities.

The nervous tissue is located in the peripheral nerves all through the body and also in the organs of the central nervous system such as the spinal cord and the brain. The nervous tissue consists of the nerve cells or the neurons. Neurons are specialized cells that react to stimuli by generating signals through the axons, which are elongated structures arising from

The cell body.

Nervous Tissue Diagram

Al-Furat Al-Awsat Technical University
Technical Institute/Kufa
Department of Medical Laboratory Techniques

The First Class
The First lecture
Histology

Function Of Nervous Tissue

1-Neurons generate and carry out nerve impulses. They produce electrical signals that are transmitted across distances, they do so by secreting chemical neurotransmitters.

2-Responds to stimuli

3-Carries out communication and integration.

3- Provides electrical insulations to nerve cells and removes debris

5-Carries messages from other neurons to the cell body

Al-Furat Al-Awsat Technical University
Technical Institute/Kufa
Department of Medical Laboratory Techniques

The First Class
The First lecture
Histology

Digestive system

The digestive tract is a long muscular tube lined with epithelium specialized for digestion and absorption of food and water. Food moves along the digestive system from the mouth where it is ingested, to the anus where the undigested and unabsorbed remnants of food and some additional waste are eliminated.

The digestive tract (a.k.a alimentary tract), starts in the oral cavity and continues through the pharynx, to the esophagus, stomach, duodenum, small intestine, large intestine, rectum, and terminates in the anal canal. Food moves along the digestive tract by peristalsis, the rhythmic contractions of the smooth muscle within the walls of the tube. Food moves in one direction (except in unusual circumstances such as vomiting), and multiple circular muscles called sphincters, located at critical junctions, prevent the food in transit from going backward. The

mucosal (epithelial layer) secretions aid in digestion, and later provide the mechanisms for the absorption of nutrients.

In addition to the digestive tract, the digestive system includes several accessory glands that secrete various enzymes and fluids to assist with digestion and transport. The major accessory glands of the digestive system include:

- Three pairs of salivary glands,
- The pancreas
- The liver with the gallbladder.

Figure 1: Segments and accessory glands of the digestive system.

The structure of the intestinal wall changes along the digestive tract, reflecting the function of the particular segment, but the general architecture remains the same.

Four layers of digestive tract walls

Walls of the digestive tract have four concentric layers. Going from the inside out, these are:

O mucosa o submucosa o muscularis externa o adventitia or serosa

Figure 2: Schematic drawing of the digestive tract layers

Mucosa:-

The mucosa is the innermost layer. It is made of:

- o epithelium o lamina propria

O muscularis mucosae (this is separate from the thicker layer of smooth muscle within the muscularis layer).

Epithelium covers the inner surface of the digestive tract. It starts as stratified squamous epithelium in the esophagus and changes to simple columnar epithelium in the stomach. In the intestines, it stays columnar but acquires microvilli to increase the surface area for absorption. The segmental characteristics of the epithelium will be described in later sections. As with every other epithelium, it lies on the basement membrane.

The lamina propria, a thin layer of loose connective tissue, lies directly below the mucosal epithelium.

The muscularis mucosae is a relatively thin layer of smooth muscle located between the mucosa and the submucosa.

Submucosa:-

The submucosa is composed of a layer of dense, irregular connective tissue. It contains large blood vessels, lymphatics and the neurons of the submucosal plexus of Meissner.

Muscularis externa:-

The muscularis, sometimes called muscularis externa to differentiate from the muscularis mucosae, consists of two clearly visible layers of smooth muscle (three in the stomach only):

- o an inner circular layer o an outer longitudinal layer

Another nerve plexus, a myenteric plexus of Auerbach, lies between the circular and longitudinal layers of smooth muscle. This muscular layer contracts to produce peristalsis.

Adventitia:-

The adventitia is the outermost layer and is a thin layer of loose connective tissue. In places, a thin layer of simple squamous epithelium called mesothelium covers adventitia on the external surface. When covered by mesothelium, the adventitia is called the serosa.

Al-Furat Al-Awsat Technical University
The First Class
Technical Institute/Kufa
The First lecture
Department of Medical Laboratory Techniques
Histology

The Liver & Spleen

The liver is the largest internal organ of the human body, weighing approximately 1.5 kg. Embryologically it develops from the foregut and it spans the upper right and part of left abdominal quadrants. Anatomically the liver consists of four lobes: two larger ones (right and left) and two smaller ones (quadrate and caudate).

Histological components:-

The liver consists of the following major histological components:

1-Parenchyma**, which is represented **by hepatocytes

2-Stroma, which is a continuation of the surrounding capsule of Glisson. It consists of connective tissue and contains the vessels. The capsule is also covered by a layer of mesothelium, arising from the peritoneum covering the liver. The connective tissue of the stroma is **type III collagen** (reticulin), which forms a meshwork that provides integrity for the hepatocytes and sinusoids.

3-Sinusoids, which are capillaries travelling between hepatocytes.

4-Spaces of Disse (perisinusoidal spaces), which are located between the hepatocytes and the sinusoids.

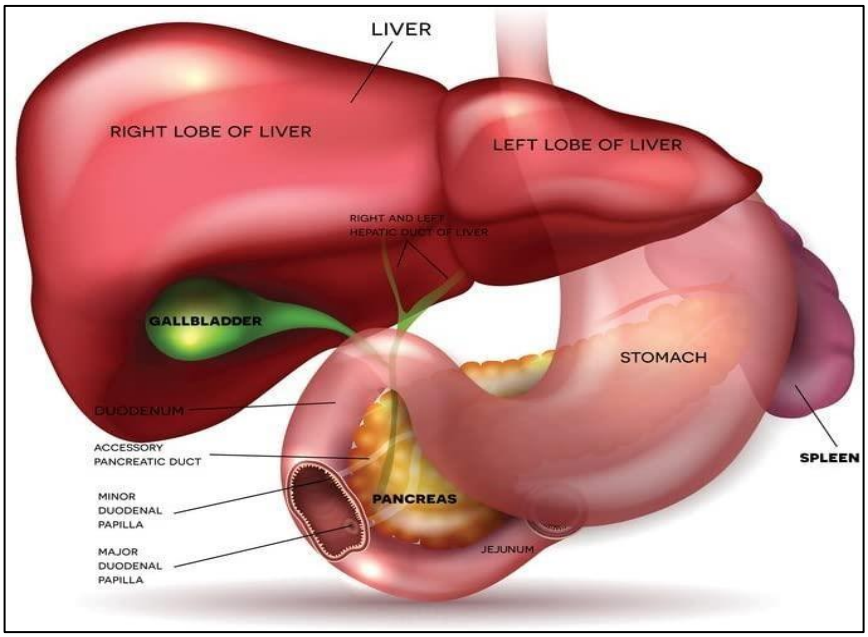

Hepatocytes

These large and **polyhedral** (six surfaces) cells make up 80% of the total cells of the liver. They can contain between **two** and **four nuclei**, which are large and spherical, occupying the centre of the cells. Each nucleus has at least **two nucleoli**. The typical lifespan of a hepatocyte is five months. The adjacent hepatocytes leave a very small space between them known as **bile canaliculi** which are almost 1.0-2.0 µm in diameter. The cell membranes near these canaliculi are joined by tight junctions.

Functions and physiology

The liver performs several important functions in the human body, such as given below:

- Production of bile, which helps carry away waste and break down fats in the small intestine during digestion
- Production of certain proteins for blood plasma
- Production of cholesterol and special proteins to help carry fats through the body
- Conversion of excess glucose into glycogen for storage (glycogen can later be converted back to glucose for energy) and to balance and make glucose as needed
- Regulation of blood levels of amino acids, which form the building blocks of proteins
- Processing of hemoglobin for use of its iron content (the liver stores iron)
- Conversion of poisonous ammonia to urea (urea is an end product of protein metabolism and is excreted in the urine)
- Clearing the blood of drugs and other poisonous substances
- Regulating blood clotting
- Clearance of bilirubin, also from red blood cells. If there is an accumulation of bilirubin, the skin and eyes turn yellow.

When the liver has broken down harmful substances, its by-products are excreted into the bile or blood. Bile by-products enter the intestine and leave the body in the form of feces.

Blood by-products are filtered out by the kidneys, and leave the body in the form of urine.

The Spleen

The spleen is a fist sized organ located in the left upper quadrant of the abdomen. It is the **largest lymphoid** organ and thus the largest filter of blood in the human body. The spleen has a unique location, embryological development and histological structure that

differs significantly from other lymphoid organs.

Special histological features define several important functions of the spleen, such as **filtering** blood, maintaining immune response balance and recycling iron. The spleen can also serve as a reservoir for additional blood in situations of acute or chronic **blood loss** (such as bleeding or anemia), as well as an alternative site for hematopoiesis (formation of blood cells and platelets) outside of bone marrow. Even though the spleen has a few unique functions that can't be replaced by other lymphoid organs, it is not a vital organ and people can live without it.

The **spleen** is an organ found in all vertebrates. Similar in structure to a large lymph node, it acts primarily as a blood filter.

The spleen plays important roles in regard to red blood cells (erythrocytes) and the immune system. It removes old red blood cells and holds a reserve of blood, which can be valuable in case of hemorrhagic shock, and also recycles iron. As a part of the mononuclear phagocyte system, it metabolizes hemoglobin removed from senescent red blood cells (erythrocytes). The globin portion of hemoglobin is degraded to its constitutive amino acids, and the heme portion is metabolized to bilirubin, which is removed in the liver.

The spleen synthesizes antibodies in its white pulp and removes antibody-coated bacteria and antibody-coated blood cells by way of blood and lymph node circulation. These monocytes, upon moving to injured tissue (such as the heart after myocardial infarction), turn into dendritic

cells and macrophages while promoting tissue healing. The spleen is a center of activity of the mononuclear phagocyte system and is analogous to a large lymph node, as its absence causes a predisposition to certain infections.

In humans the spleen is purple in color and is in the left upper quadrant of the abdomen.

Enlarged spleen

Main article: Splenomegaly

Enlargement of the spleen is known as splenomegaly. It may be caused by sickle cell anemia, sarcoidosis, malaria, bacterial endocarditis, leukemia, pernicious anemia, Gaucher's disease, leishmaniasis, Hodgkin's disease, and tumours .

The most common cause of acute splenomegaly in children is viral infection, which is transient and usually moderate. Basic work-up for acute splenomegaly includes a complete blood count with differential, platelet count, and reticulocyte and atypical lymphocyte counts to exclude hemolytic anemia and leukemia. Assessment of IgM antibodies to viral capsid antigen (a rising titer) is indicated to confirm Epstein–Barr virus or cytomegalovirus. Other infections should be excluded if these tests are negative.

Al-Furat Al-Awsat Technical University

The First Class
Technical Institute/Kufa
The First lecture
Department of Medical Laboratory Techniques
Histology